international bowel ULTRASOUND GROUP

IBUS Module 1 Workshop

Team Challenge

Group: _____

Room: _____

Intestinal Ultrasound Report

INDICATIONS AND DISEASE CHARACTERISTICS

_____

Previous abdominal surgery:

_____

Segment Measurements

Ascending Colon	
BWT mm	
CDS (0-3)	
i-FAT (y/n)	
BWS	
Haustration (y/n)	

Transverse Colon	
BWT mm	
CDS (0-3)	
i-FAT (y/n)	
BWS	
Haustration (y/n)	

Descending Colon	
BWT mm	
CDS (0-3)	
i-FAT (y/n)	
BWS	
Haustration (y/n)	

Cecum	
BWT mm	
CDS (0-3)	
i-FAT (y/n)	
BWS	

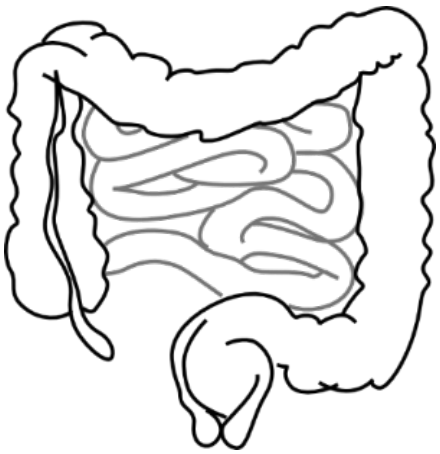

Sigmoid Colon	
BWT mm	
CDS (0-3)	
i-FAT (y/n)	
BWS	
Haustration (y/n)	

Legend

BWS (bowel wall stratification):
N = normal
P = partially abrogated
C = completely abrogated

Modified Limberg Score:
0 = no vascularization
1 = short vascular signals
2 = longer vascular signals
3 = vascular signals extending into the mesentery

Terminal Ileum	
BWT mm	
CDS (0-3)	
i-FAT (y/n)	
BWS	

Disease Extension **Lymph nodes** **Free fluid** **Complications**	**Quality of Examination** **Limitations**

Conclusion