

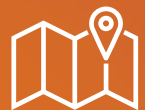

international bowel  
ULTRASOUND GROUP

# How to perform Intestinal Ultrasound

**Katharina Riegler**

Municipal Hospital Lüneburg, Germany




Lüneburg, Germany, March 13th – 14th, 2026

# Preparation (patient)

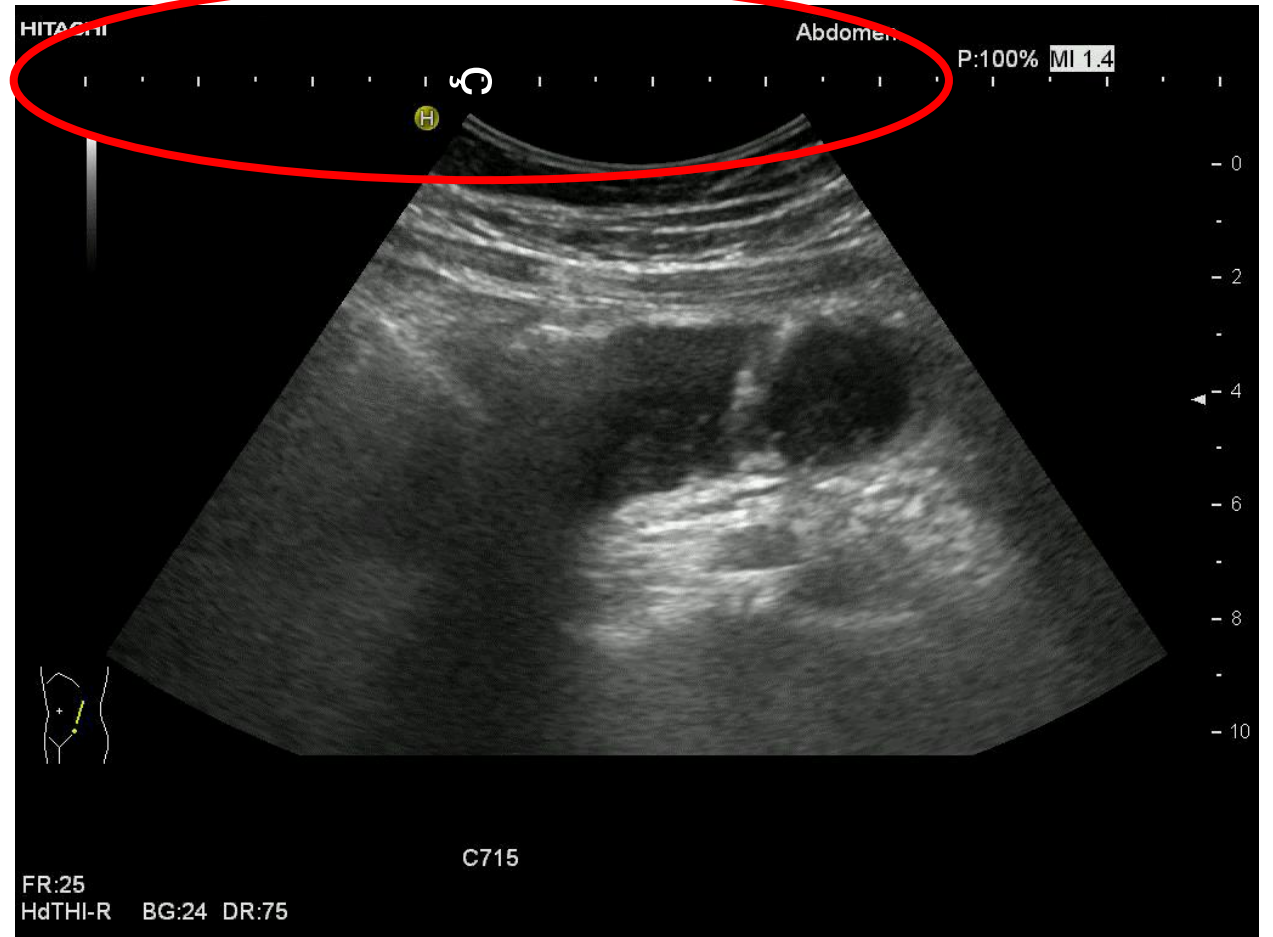
## Fasting

- not necessary
- >4 h → reduce amount of food and air in the small bowel
- >6 h → recommended before assessing splanchnic blood flow and GI motility

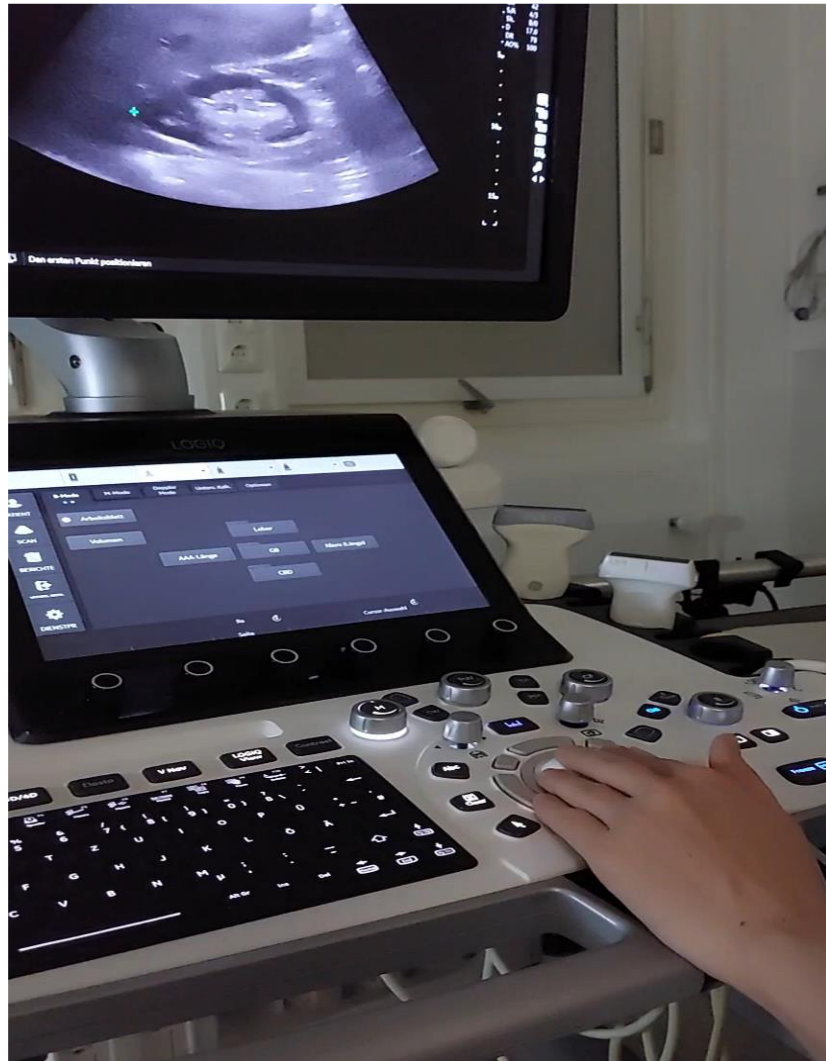

# Prepare the machine – Insert patient's details

- Check patient ID / details
- Save examination when you finish



# Ultrasound machine



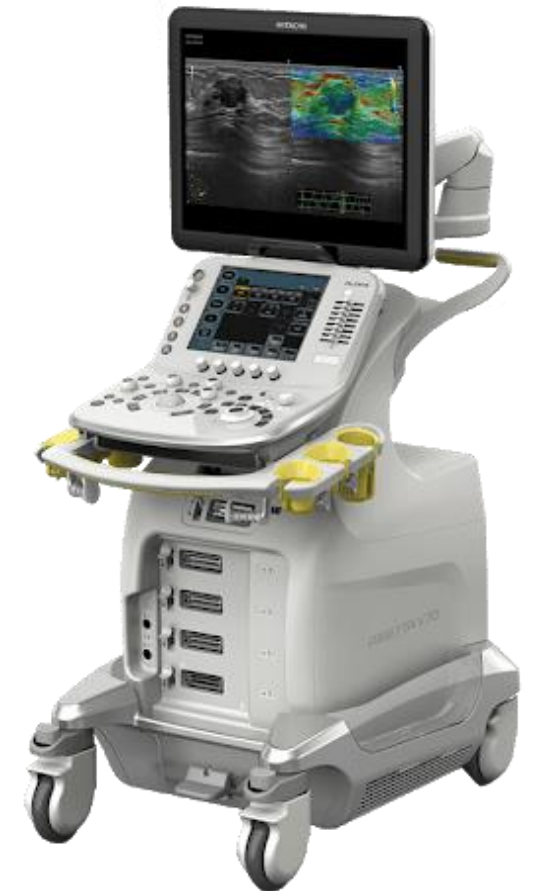Monitor

Touchscreen

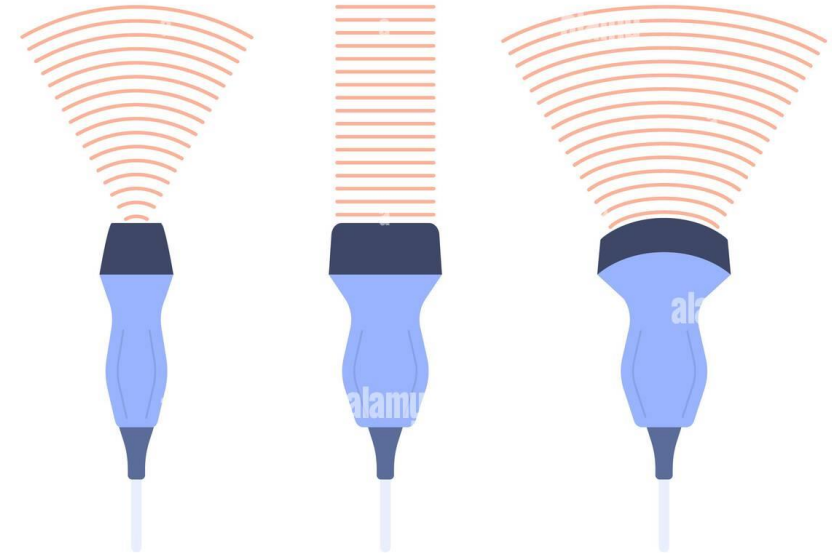

Probes

Control panel

Gel



# Ultrasound probes



PHASED ARRAY

LINEAR

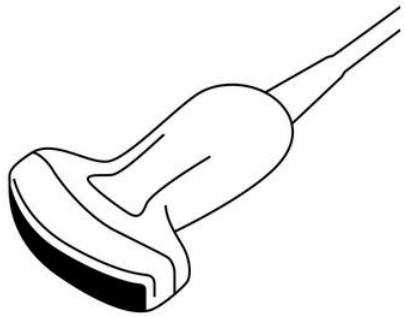
CURVILINEAR

## ULTRASOUND PROBE TYPES

Frequency

# Properties of the different probes

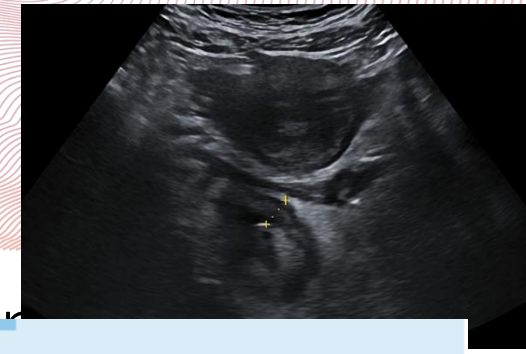
**Low frequency:** 1-6 MHz, overview, more depth, less resolution



curved array for a larger field, c  
pathology

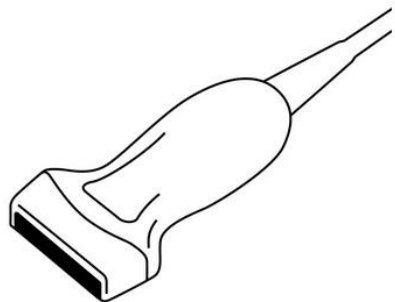
## RECOMMENDATIONS:

1. For a complete examination of the bowel both a low and high resolution probe are needed, LoE 5, GoR C, Strong consensus 13/13
2. A probe with a frequency above 5 MHz should be used when measuring wall thickness, LoE 4, GoR B, Strong consensus 13/13

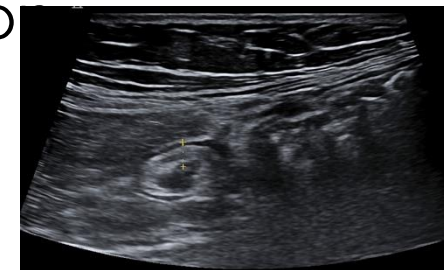


*Nylund K et al. EFSUMB Recommendations and Guidelines for Gastrointestinal Ultrasound, Ultraschall Med 2017*

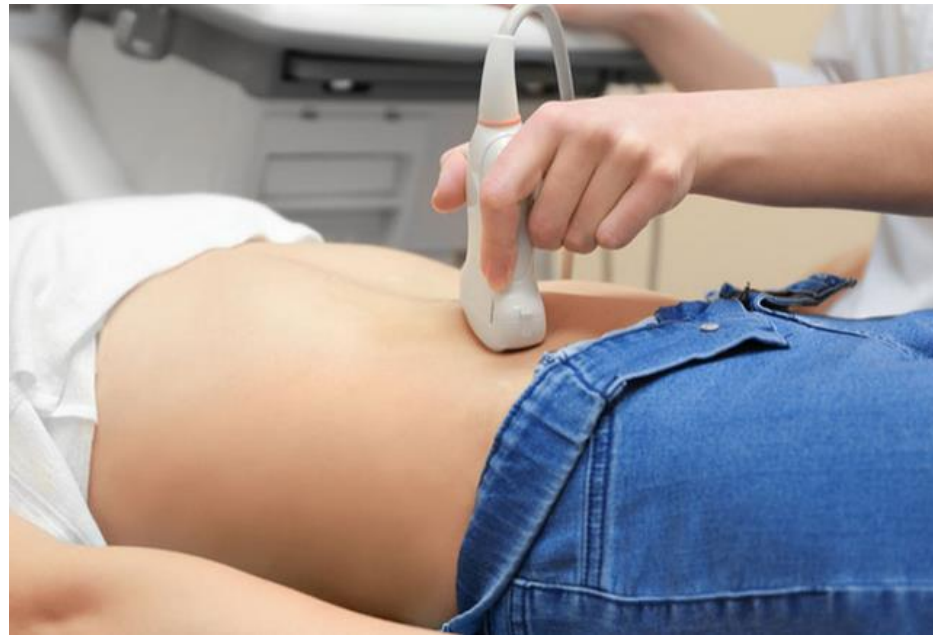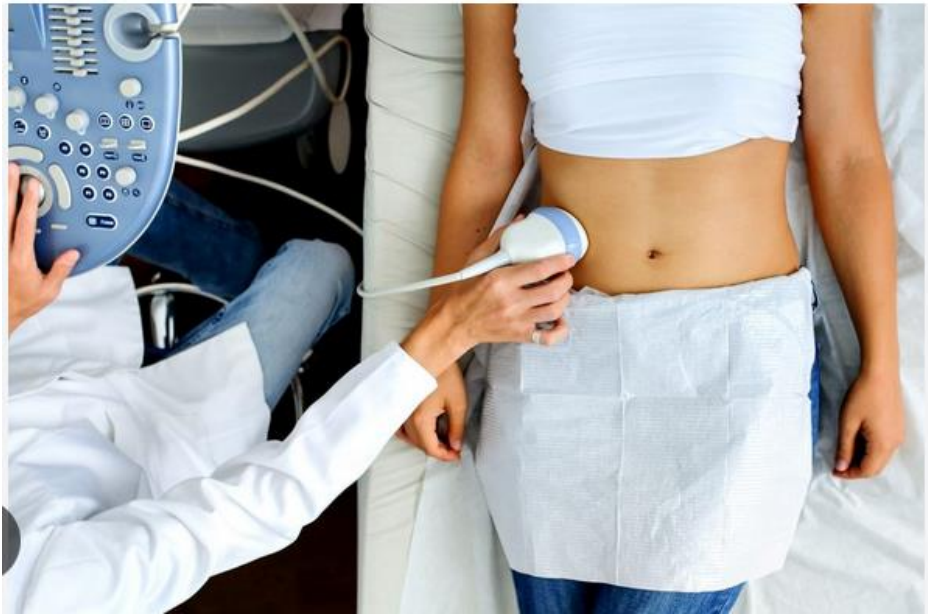**High frequency:** > 5MHz (5-10 MHz), only surface accessible (8-10 cm depth



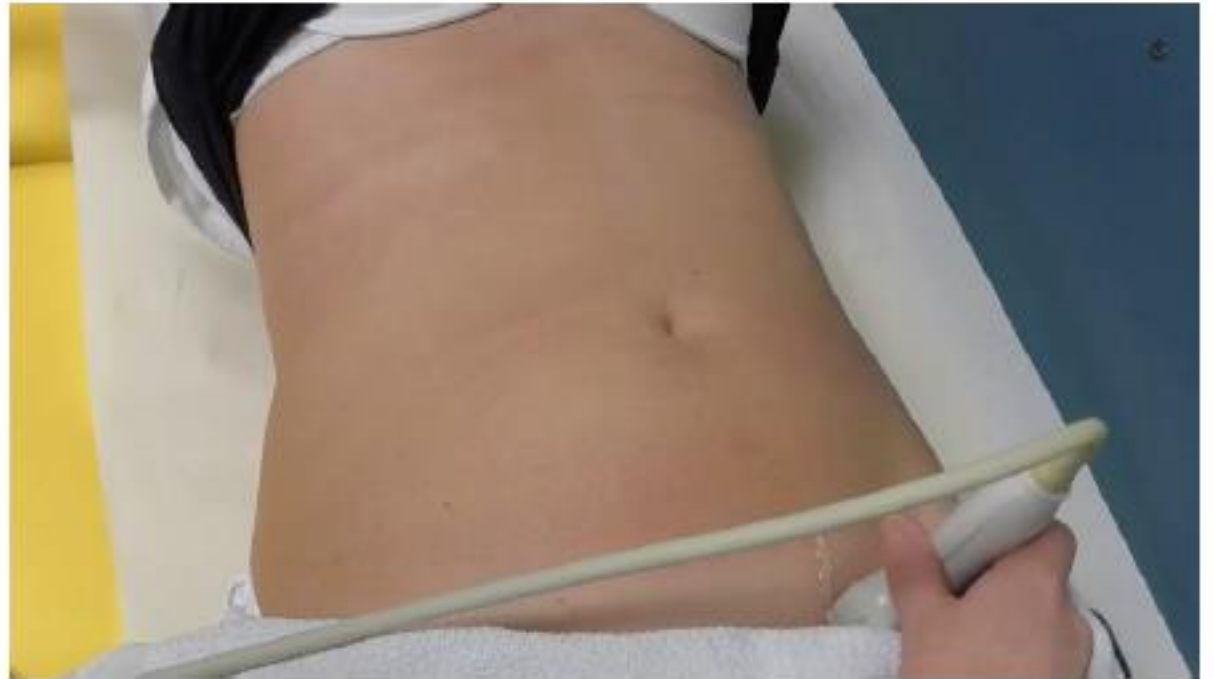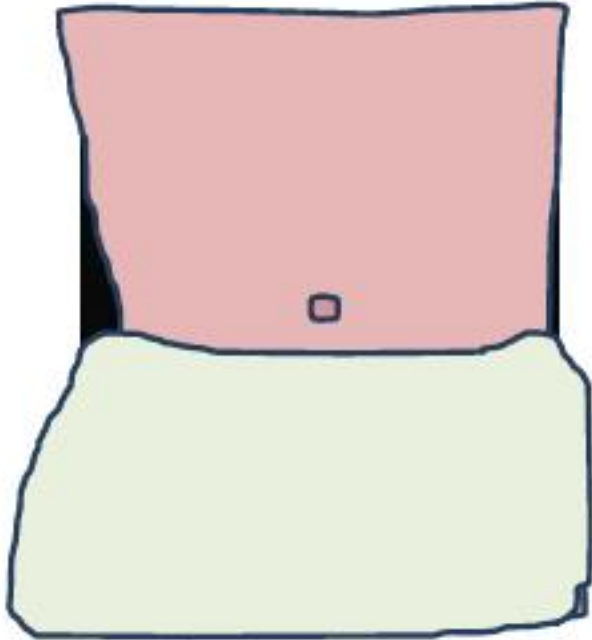
penetration), high resolution, detailed examination  
(discrimination of stratification of the bowel wall)

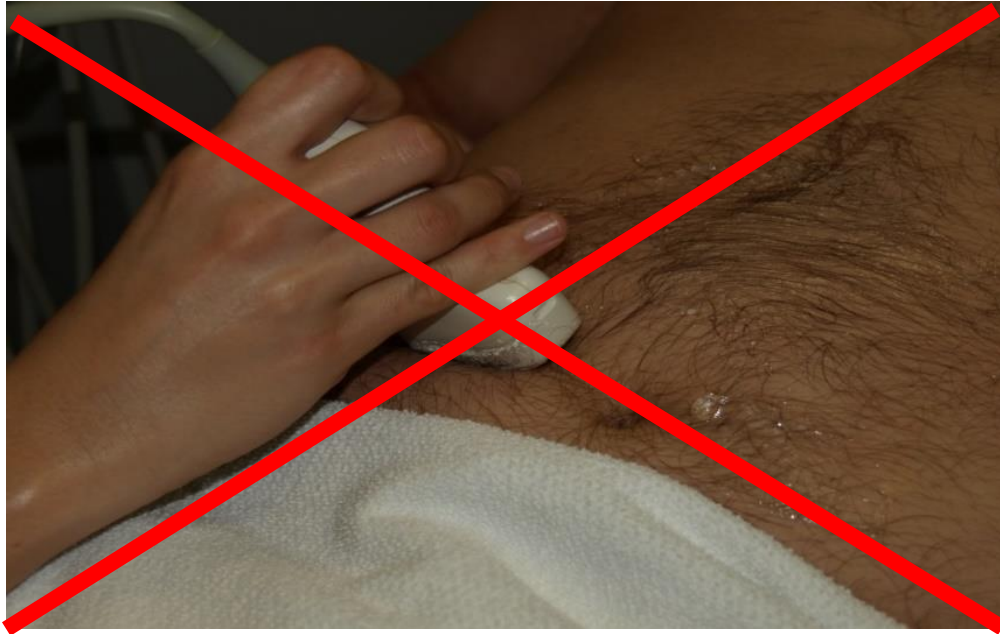


# Ultrasound technique

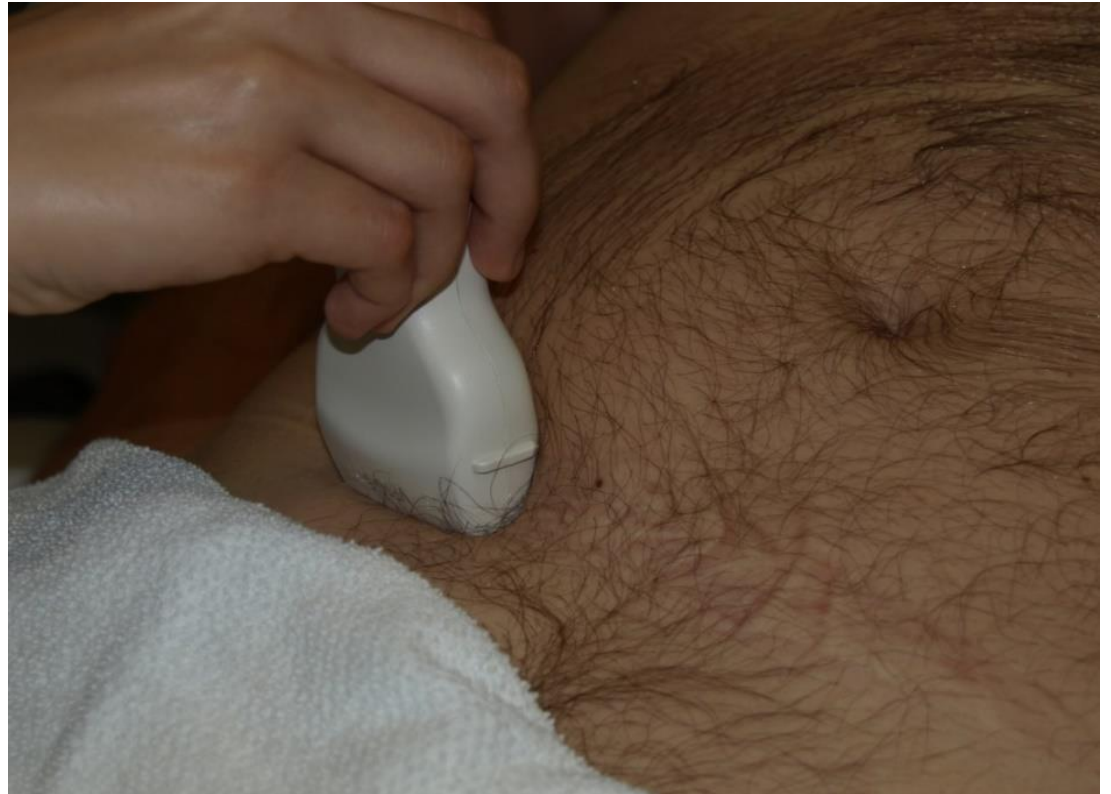

# Prepare the patient

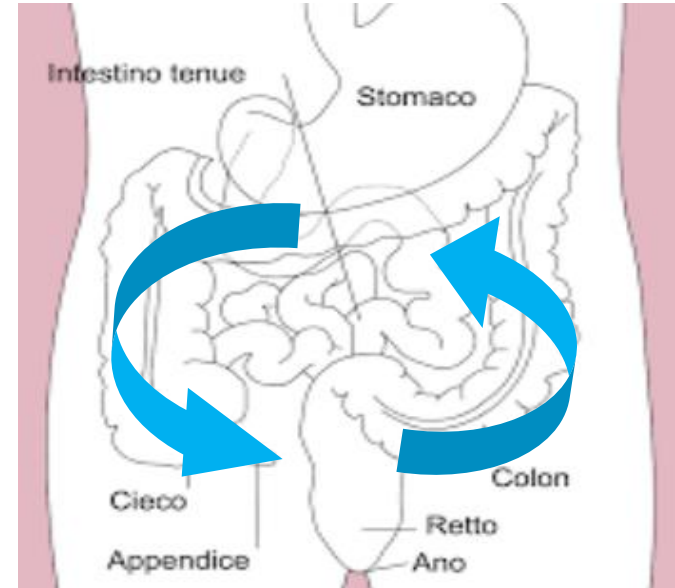
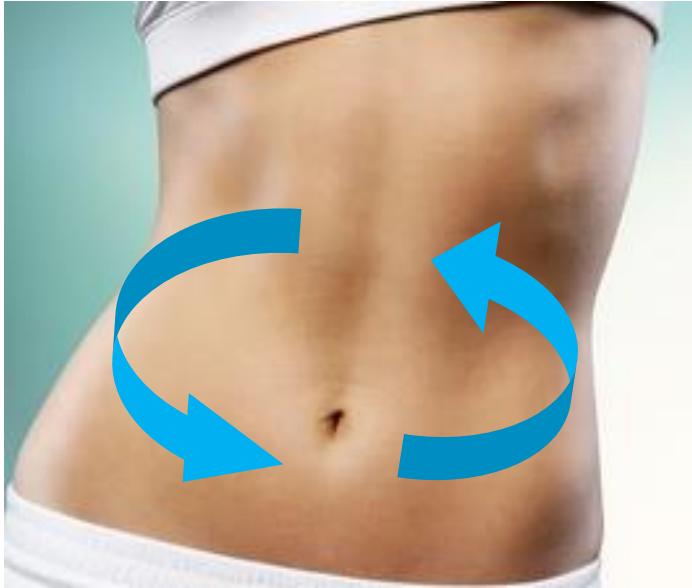




- Expose abdominal area adequately
- Water-based ultrasound gel
- Hold the probe correctly

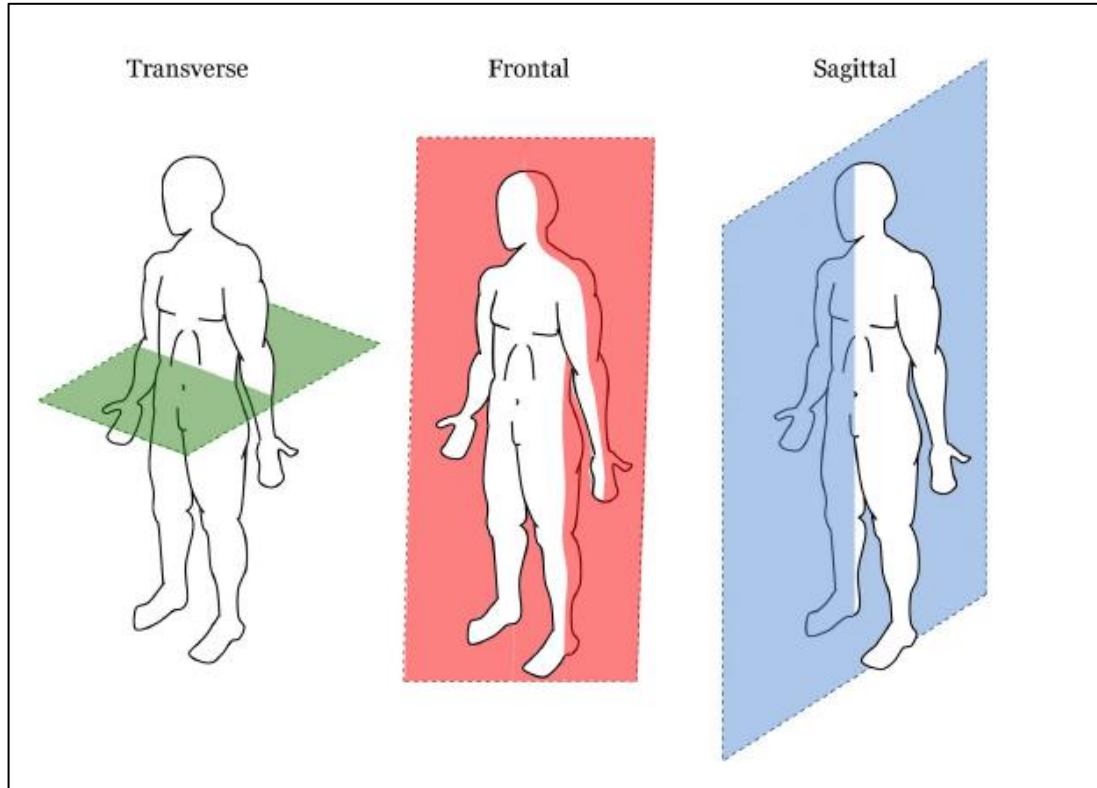


# Ultrasound technique

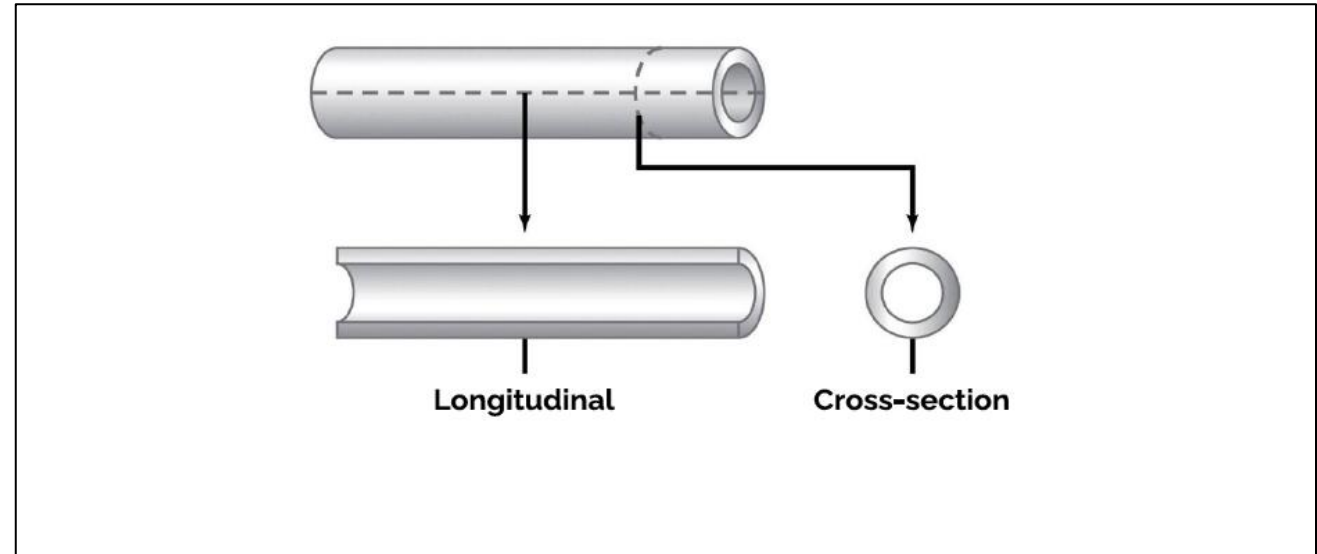



In a segment-wise manner, **all portions** of the bowel are scanned in long and short axes, and images are simultaneously captured to ensure **a continuous assessment**

# Scan planes



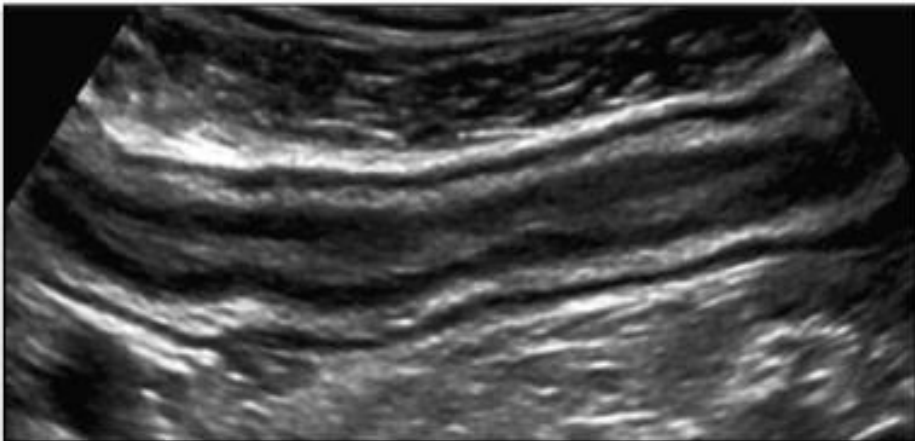
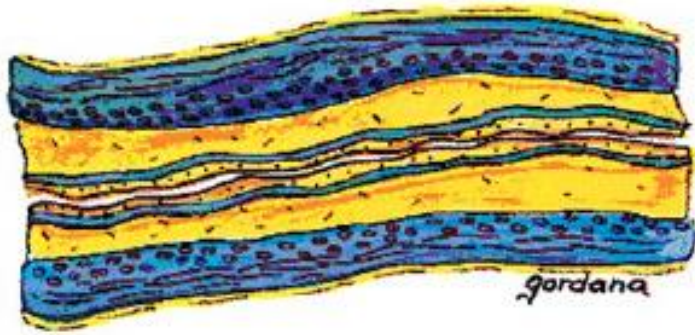
Imaging



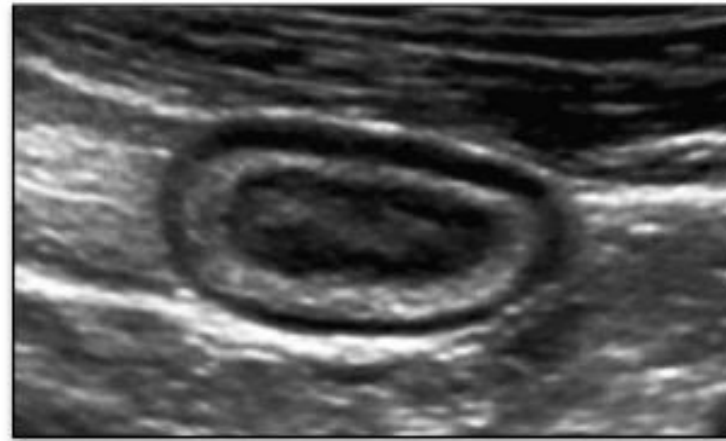
Intestinal ultrasound

# Scan planes

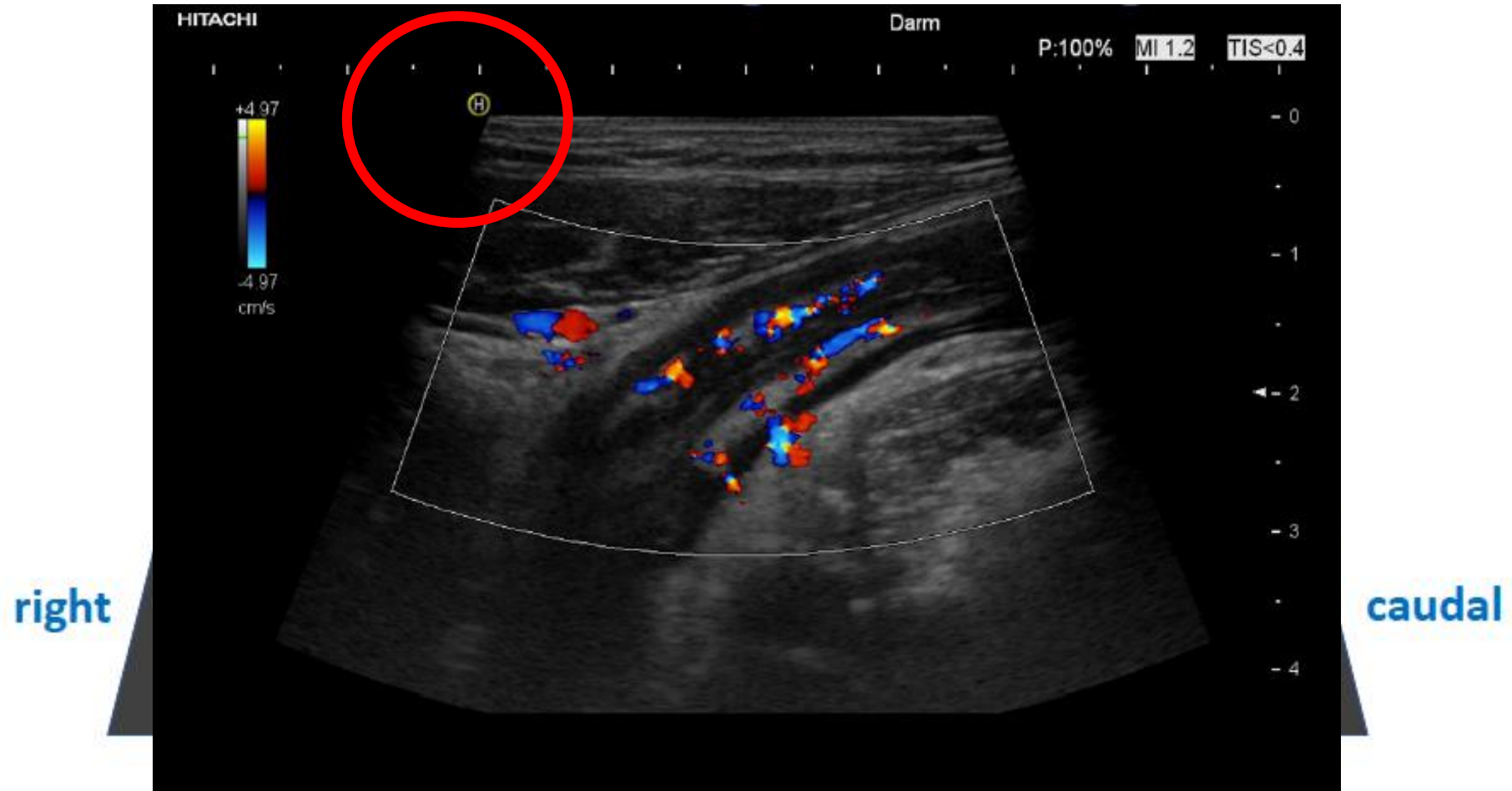

Longitudinal



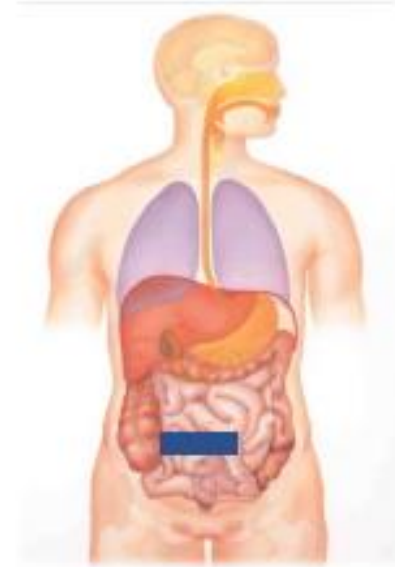
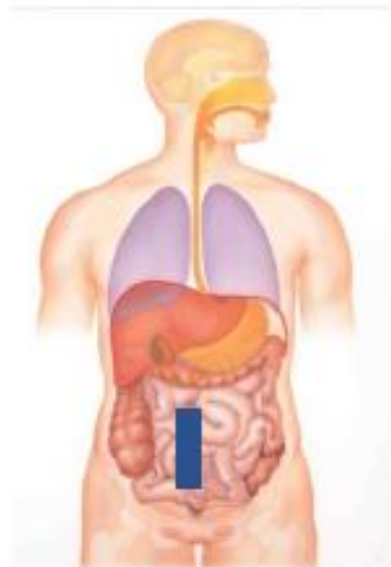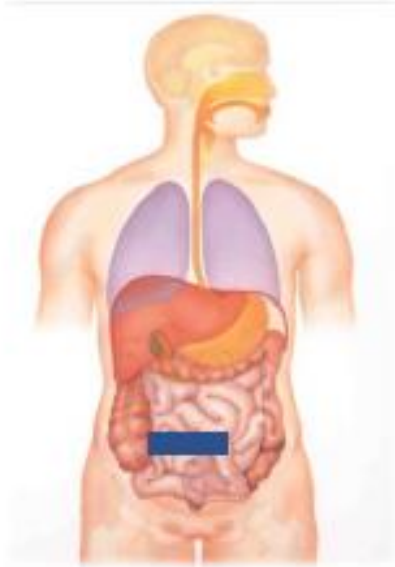Cross-section

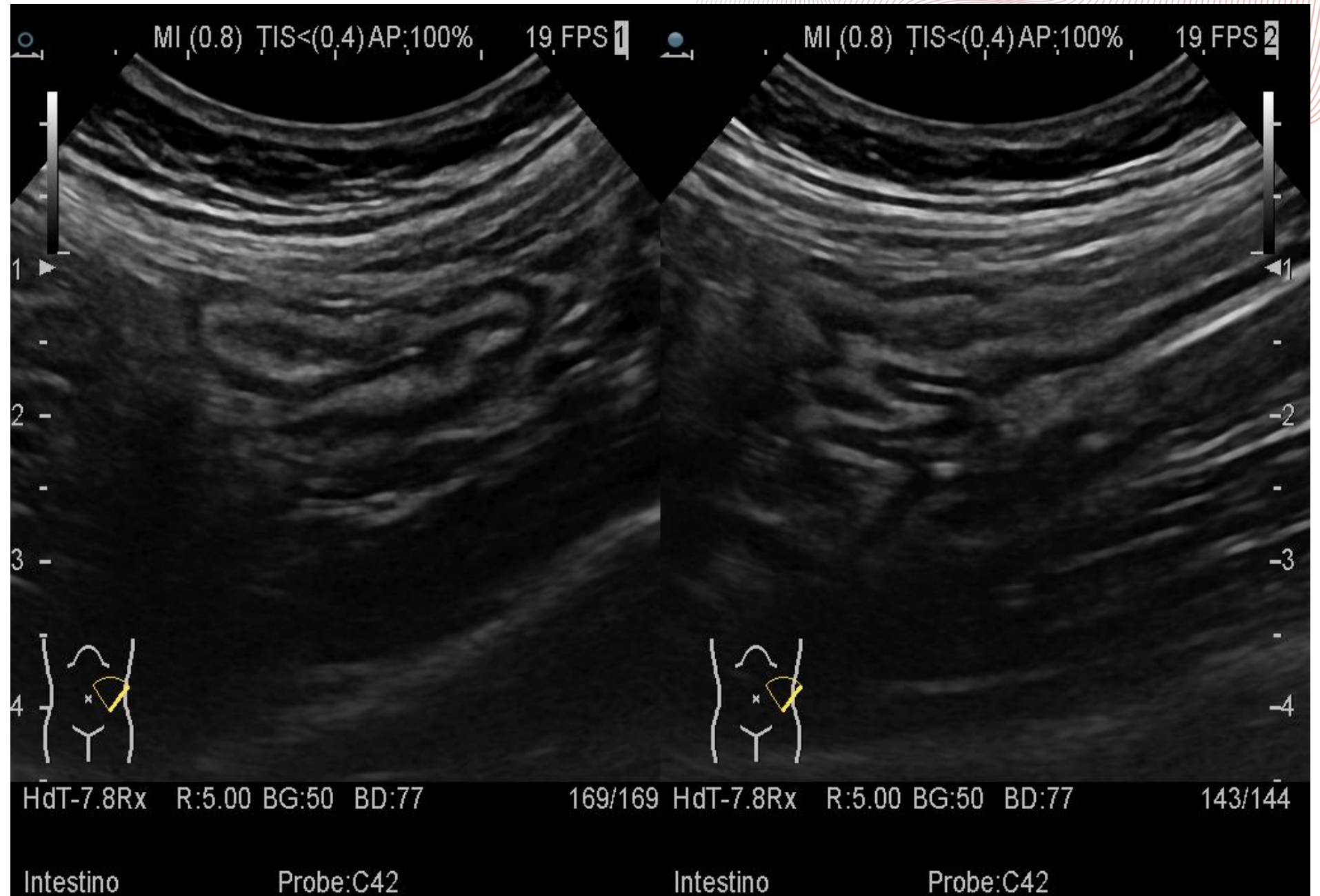
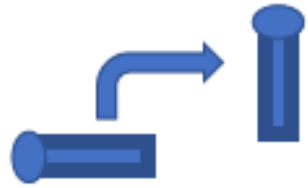


# Probe orientation




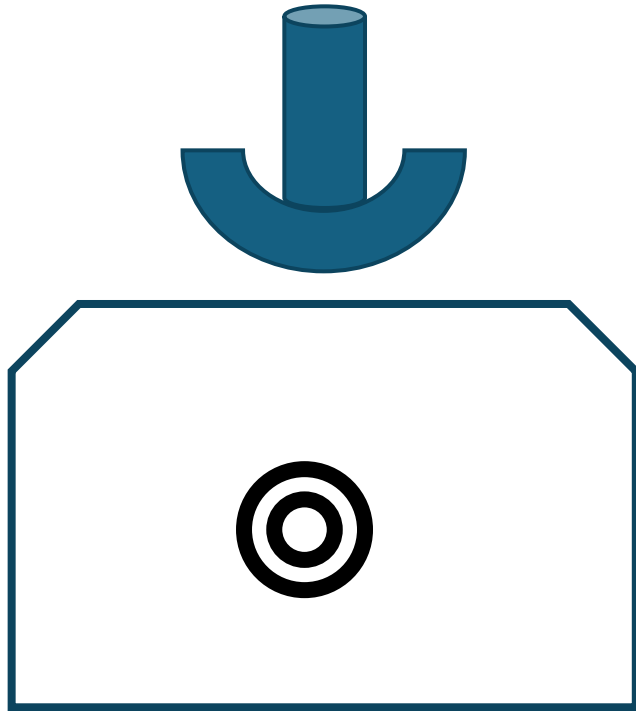
# Turning the probe






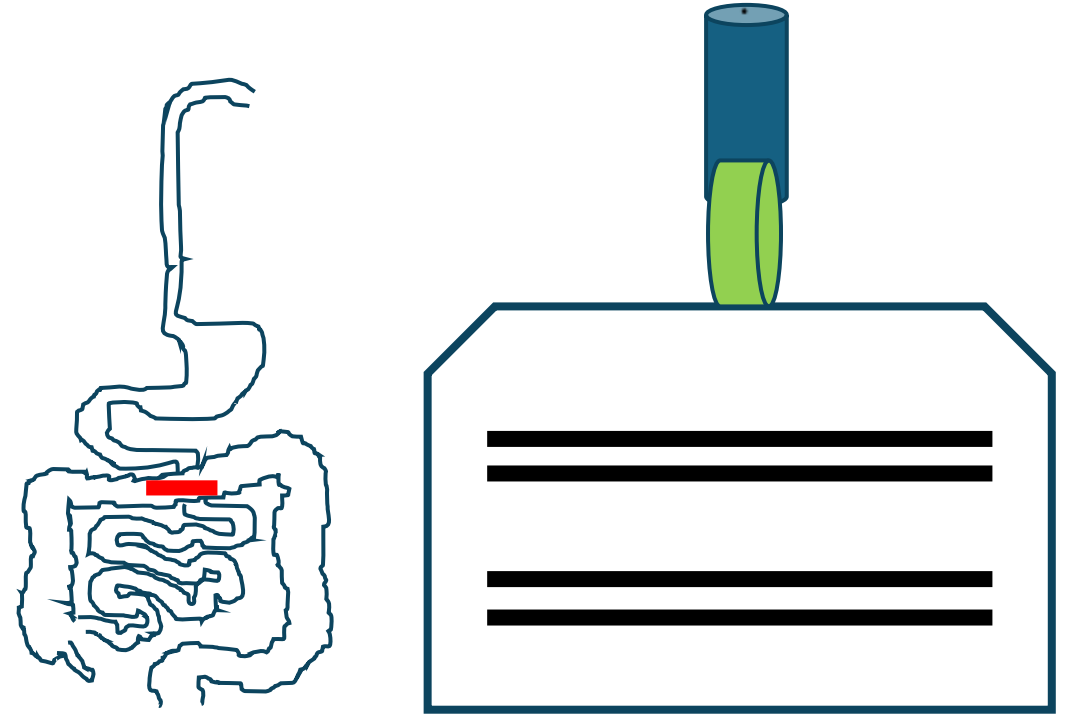
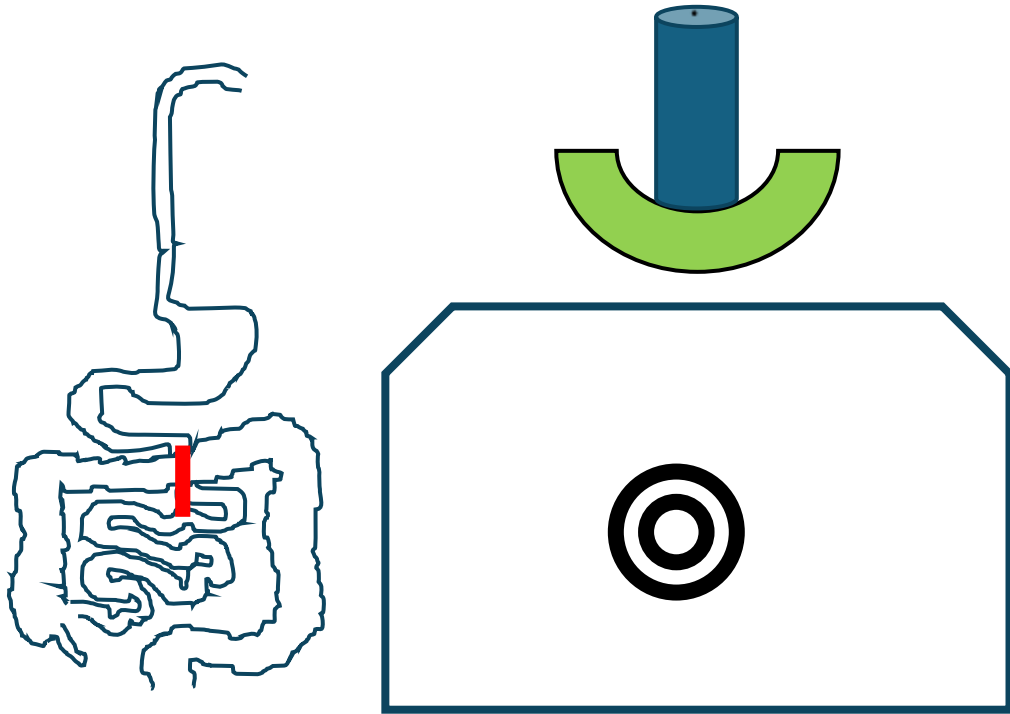



# Keep your region of interest in the center



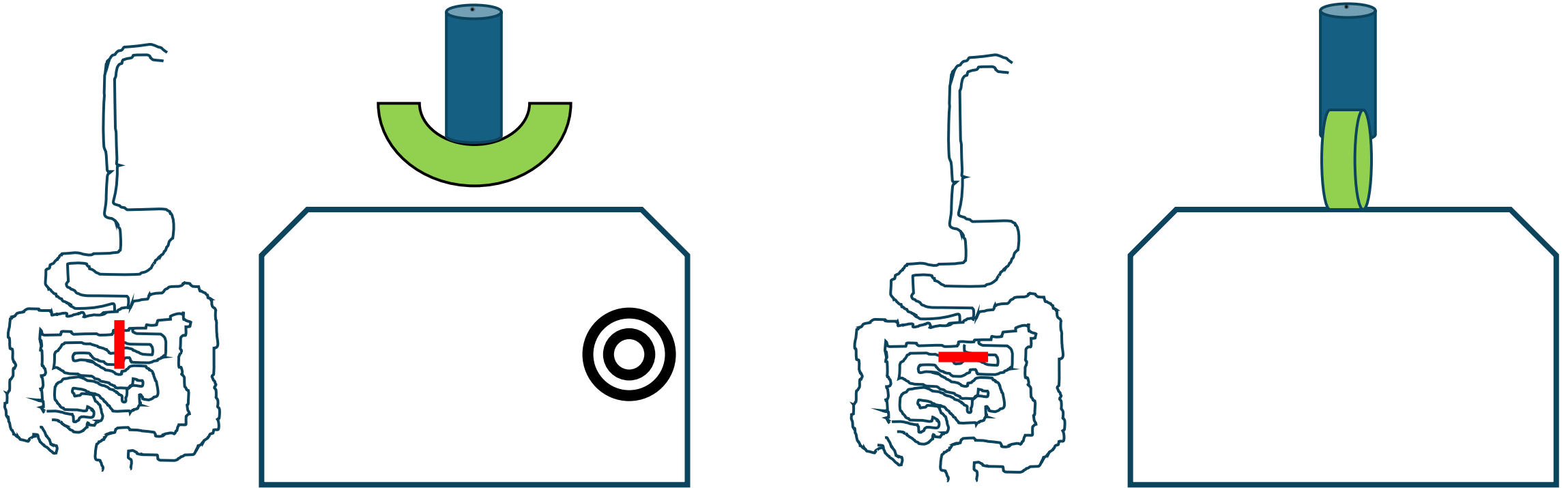


# Keep your region of interest in the center



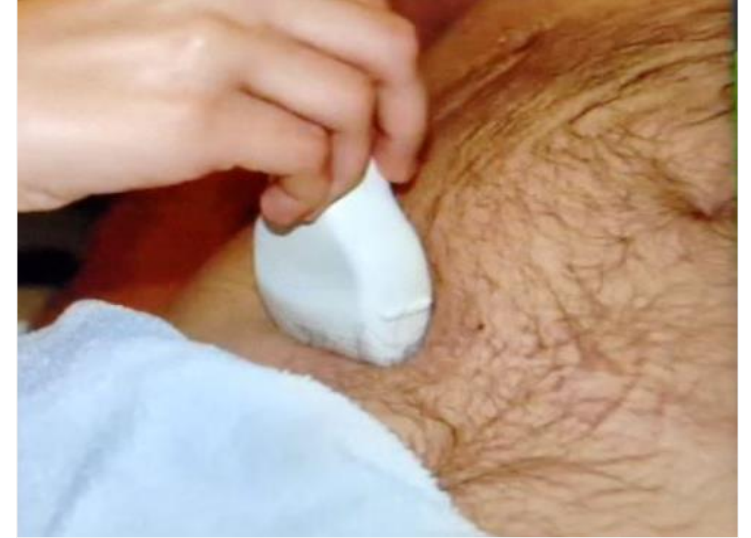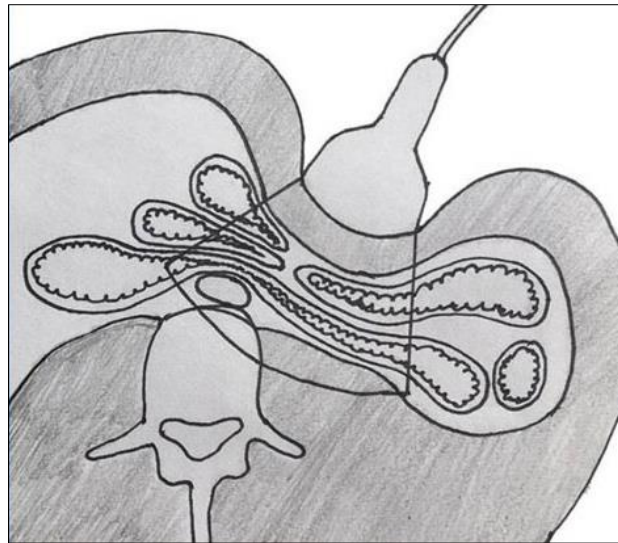
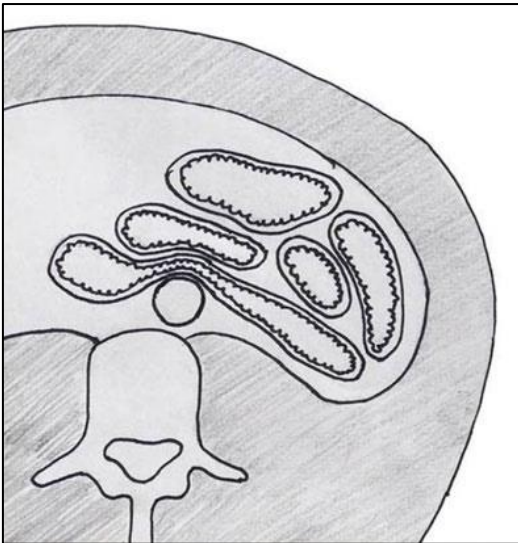


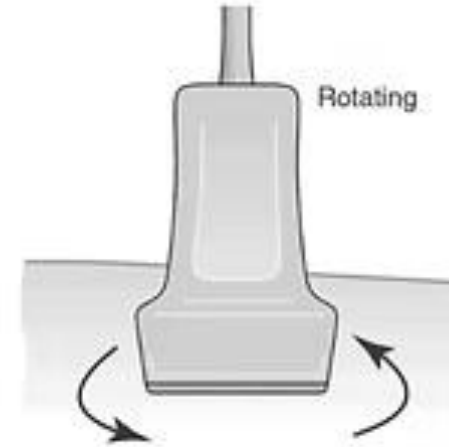
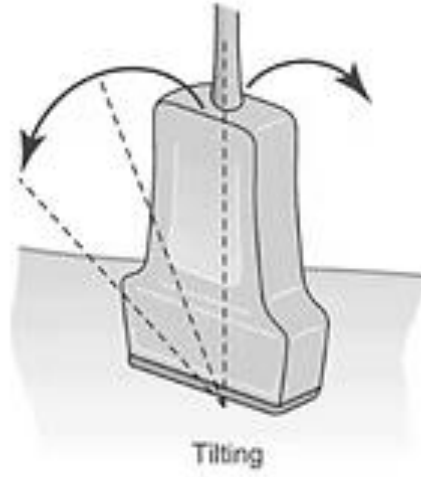
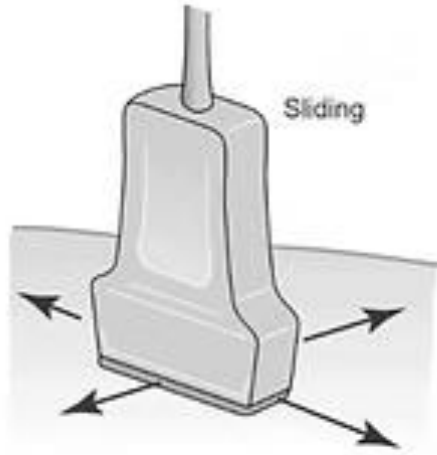

# Keep your region of interest in the center




# Examination technique

- **Probe movement**
  - set and tilt, not chaotic movement
- **Graded compression method**
  - visualization of deep areas using HF probe







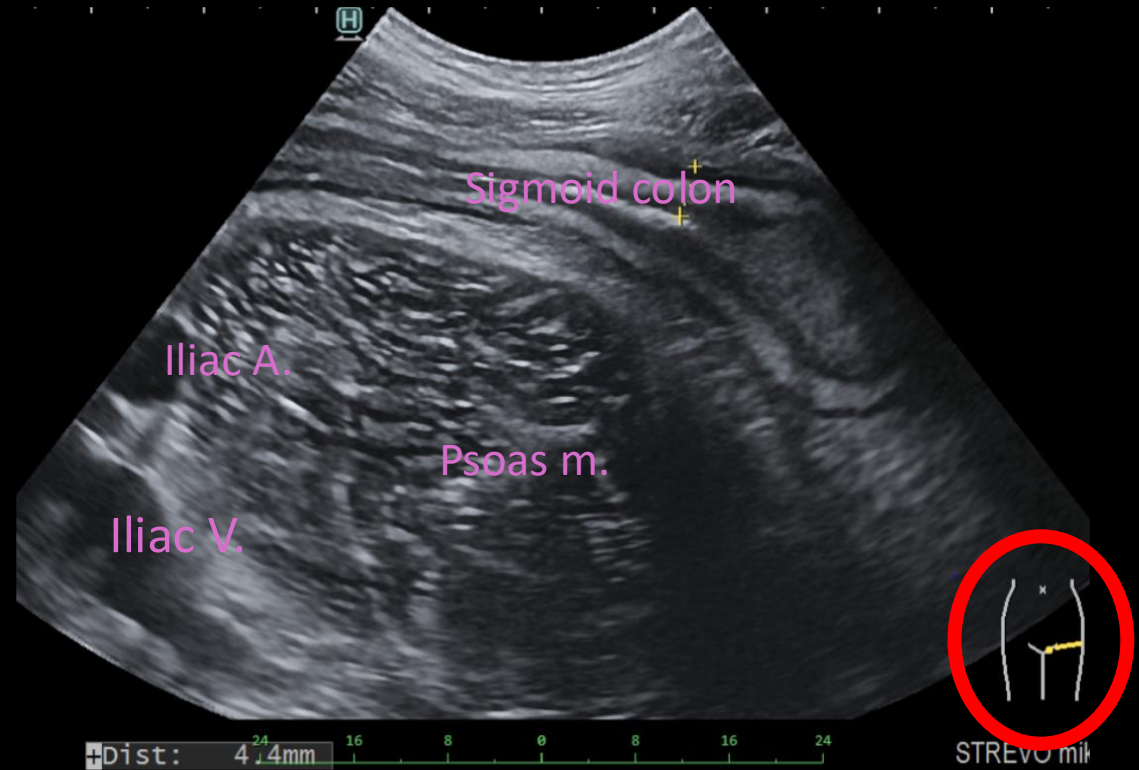
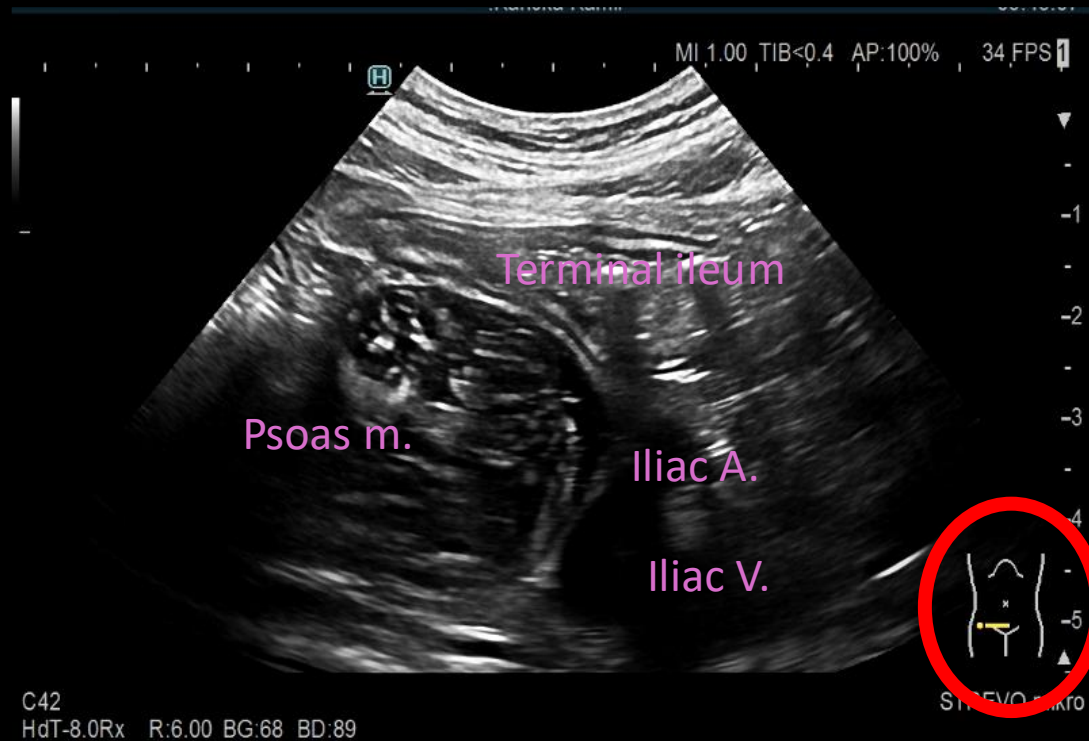
# What to look for

- Recognize the different parts of the bowel and surrounding structures
  - **Landmarks!!**
- Normal vs. abnormal bowel wall



# Localization of the key anatomy (landmarks)

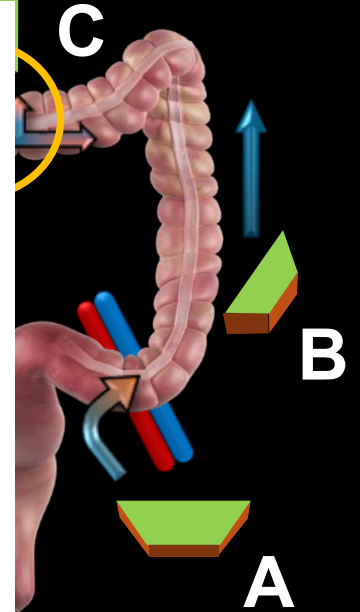
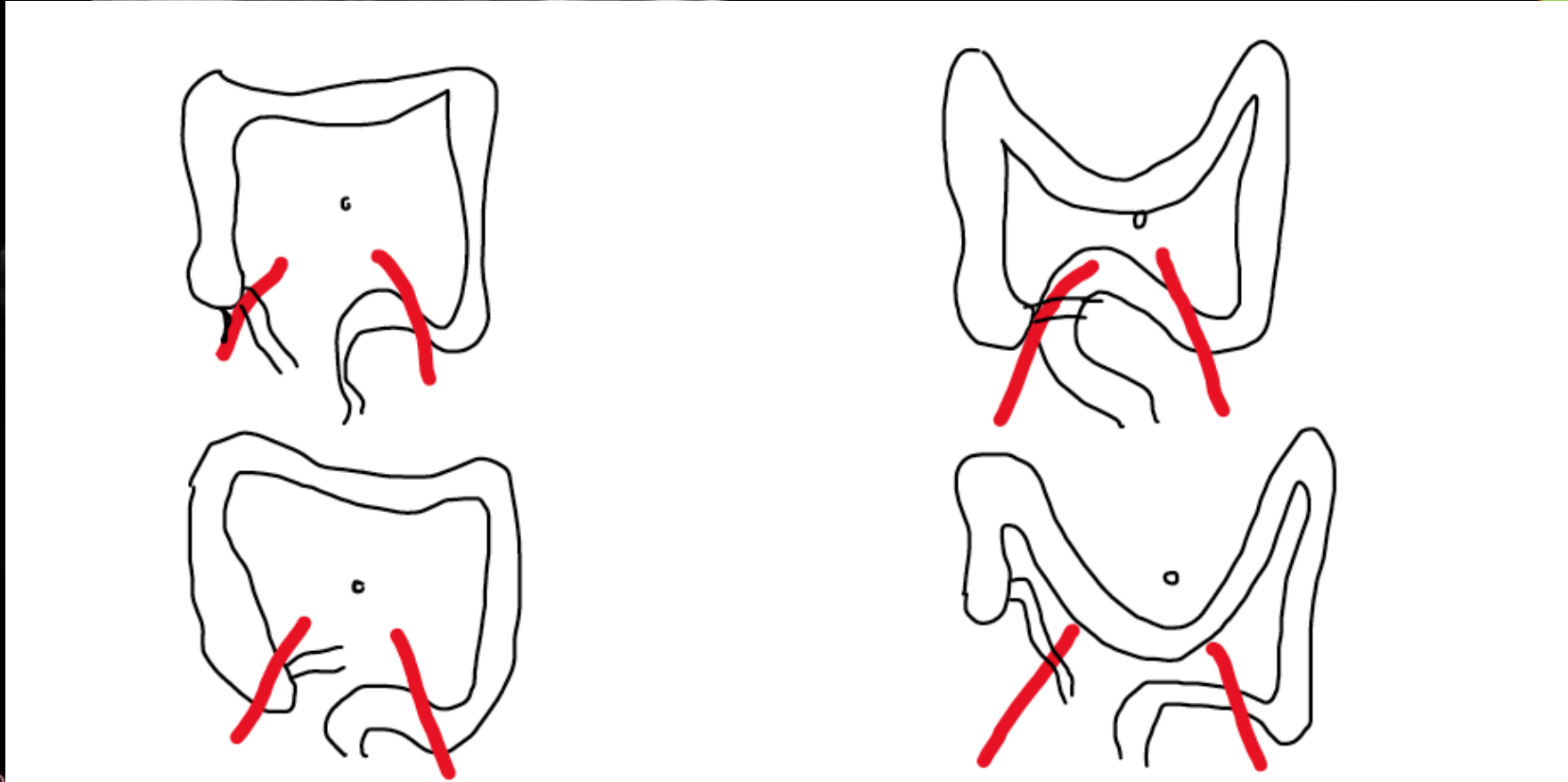
The most important landmarks: iliac vessels and the psoas muscle





# Anatomical landmarks in the mid upper abdomen – Finding the Transverse

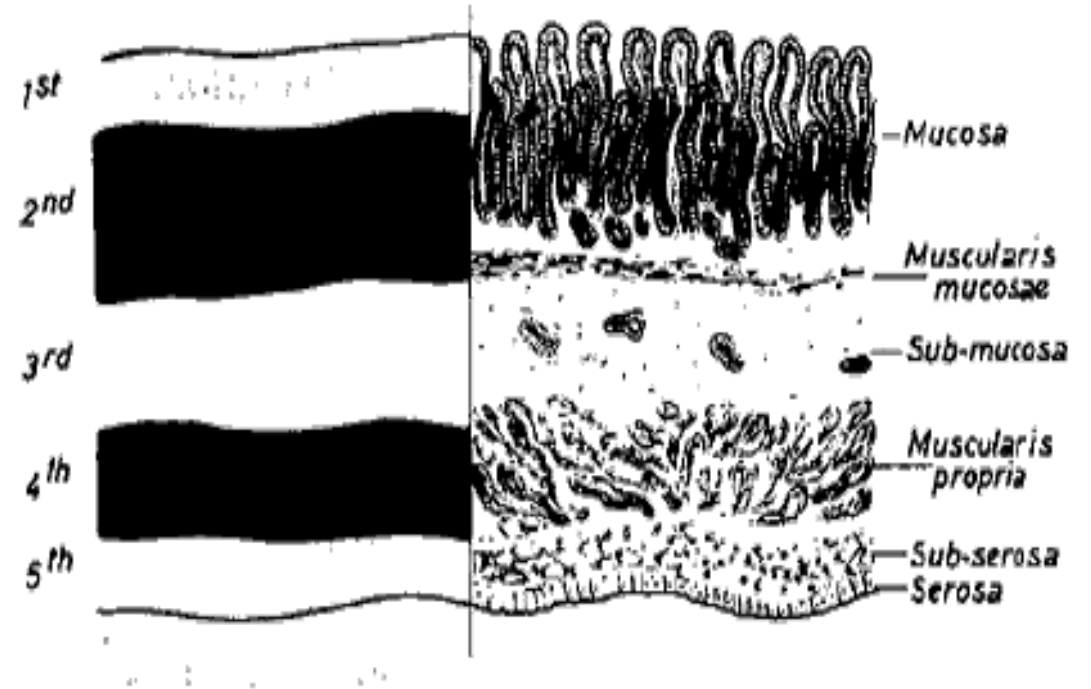
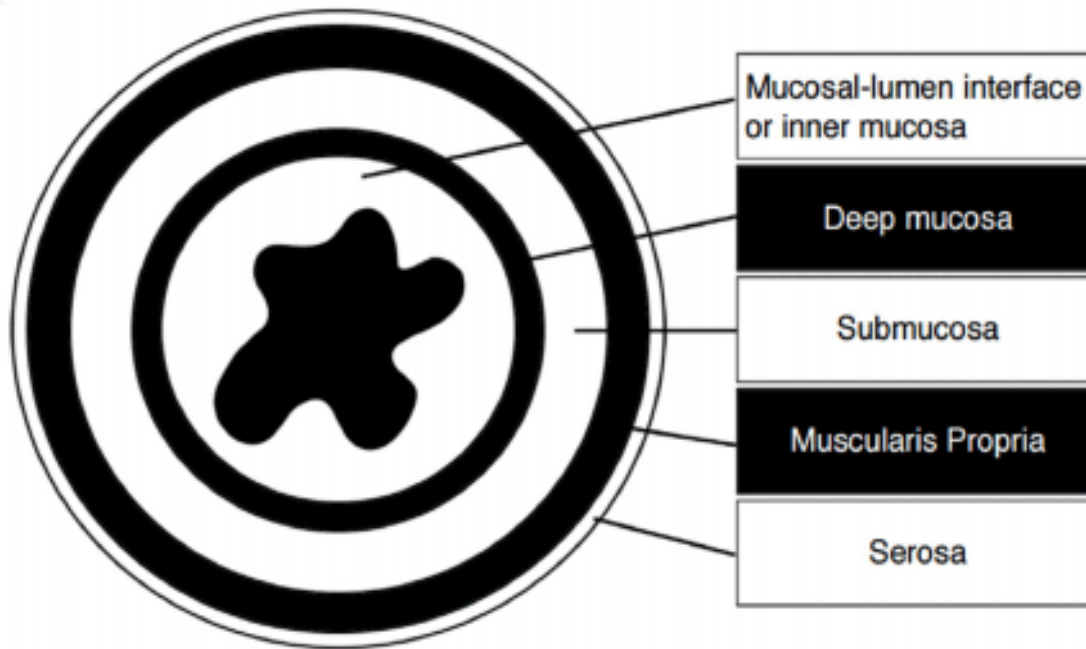
14.11.2023 15:08:06 ADM 9L Darm MI 1.3 TIs 0.8  
Se: 12 S8  
Lossy compression (JPEG)



WL: 127 WW: 256 [D]

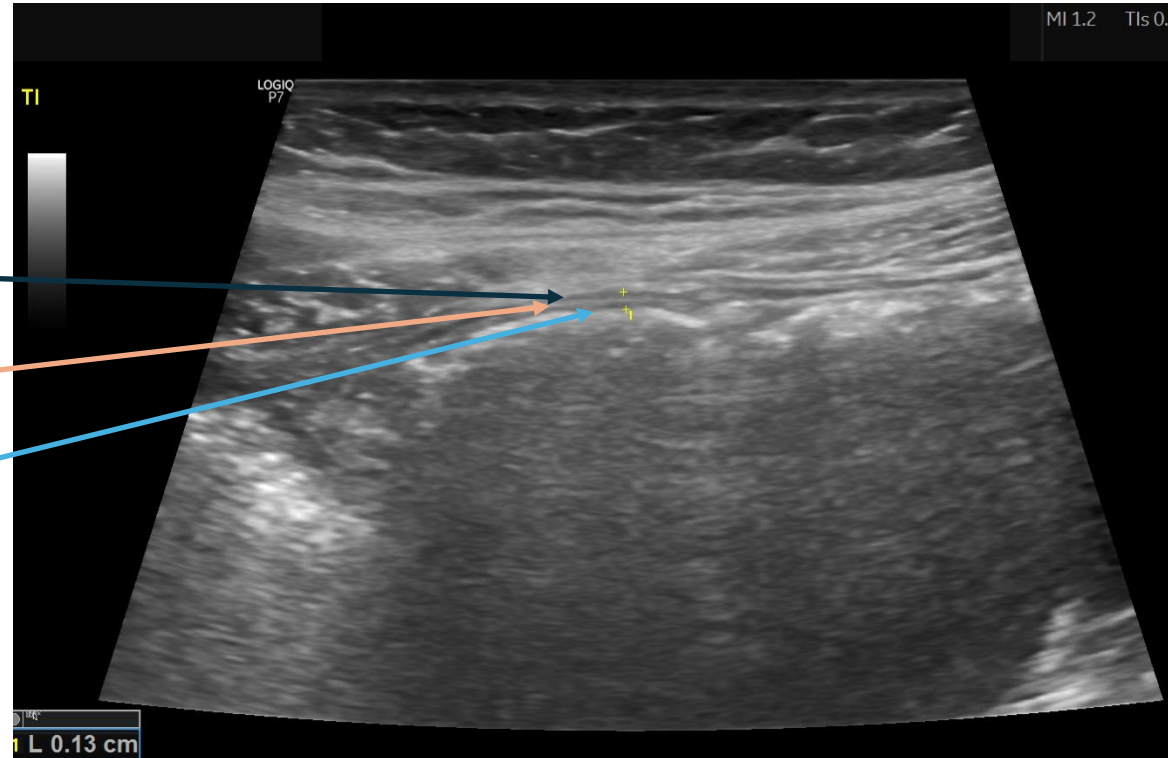
# Normal bowel wall

- 5 distinct sonographic layers



# Normal bowel wall in ultrasonography

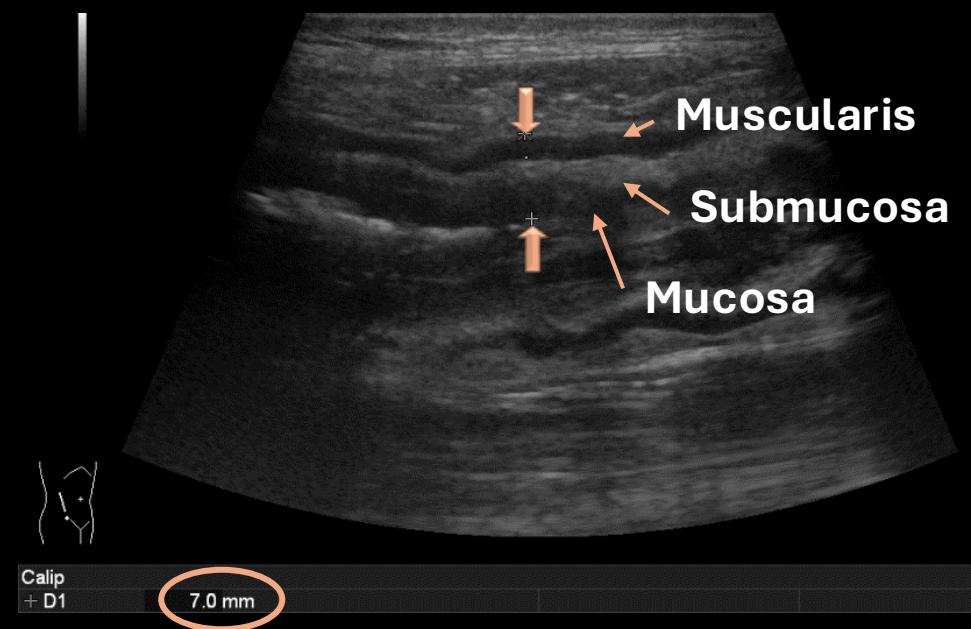
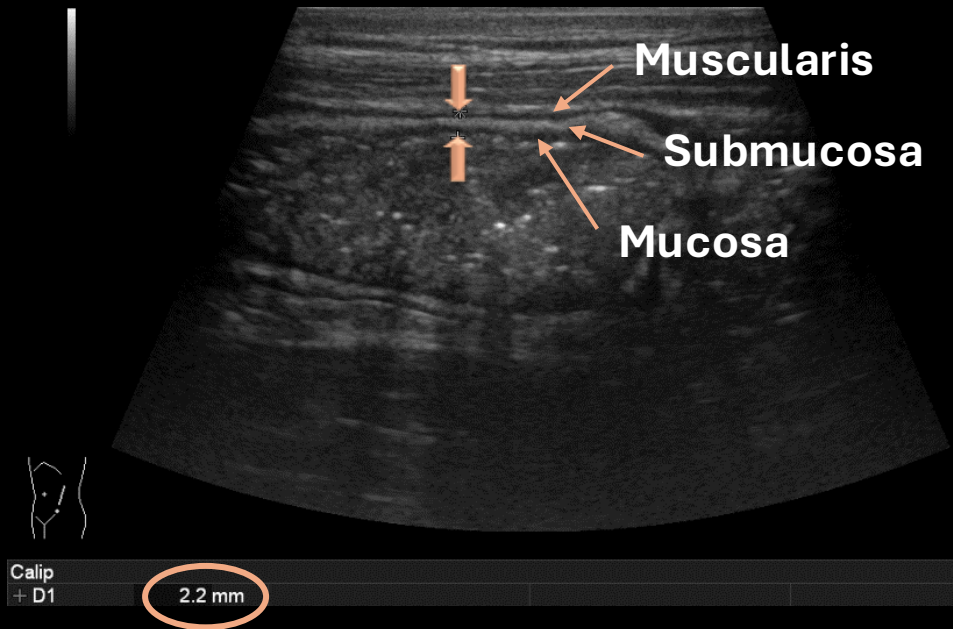
- Muscularis (hypoechoic)
- Submucosa (hyperechoic)
- Mucosa (hypoechoic)



## Some practical points:

- Interface echo of serosa mixed in with interface from peritoneum
- Posterior bowel wall often not possible to see due to air in the lumen → **Measurements in anterior wall!**
- Measure from mucosal hypoechoic layer to muscularis hypoechoic layer
- Avoid measuring at points of haustrations and mucosal folds (overestimation!)
- Keep probe perpendicular to GI wall

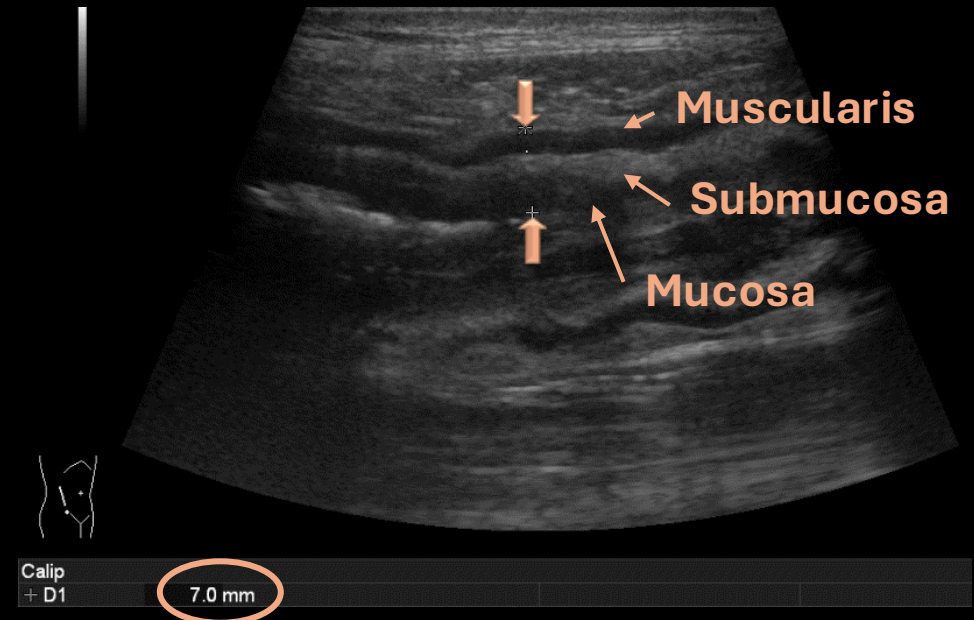
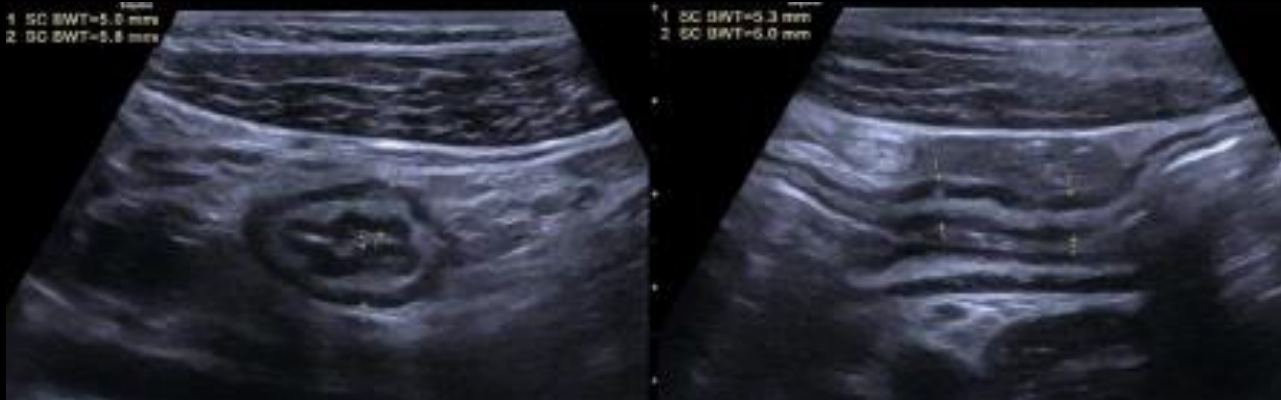
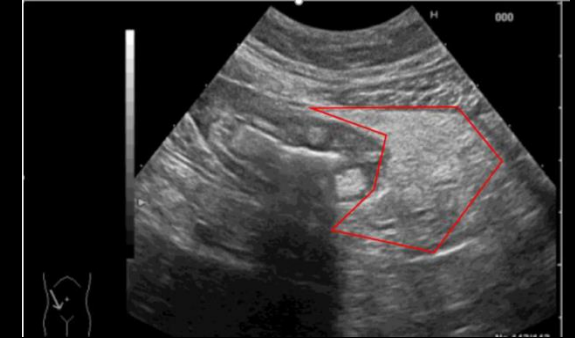
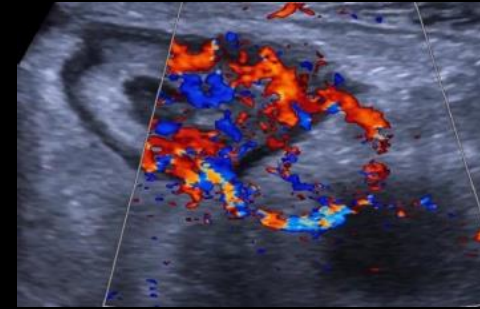
# Bowel wall thickness (BWT)



\*Measure at right angles to bowel wall layers.

# Parameters

- ✓ BWT
- ✓ Stratification
- ✓ Vascolarization
- ✓ Margins
- ✓ Austra
- ✓ Motility
- ✓ Mesentery
- ✓ Lymph nodes
- ✓ Free fluid



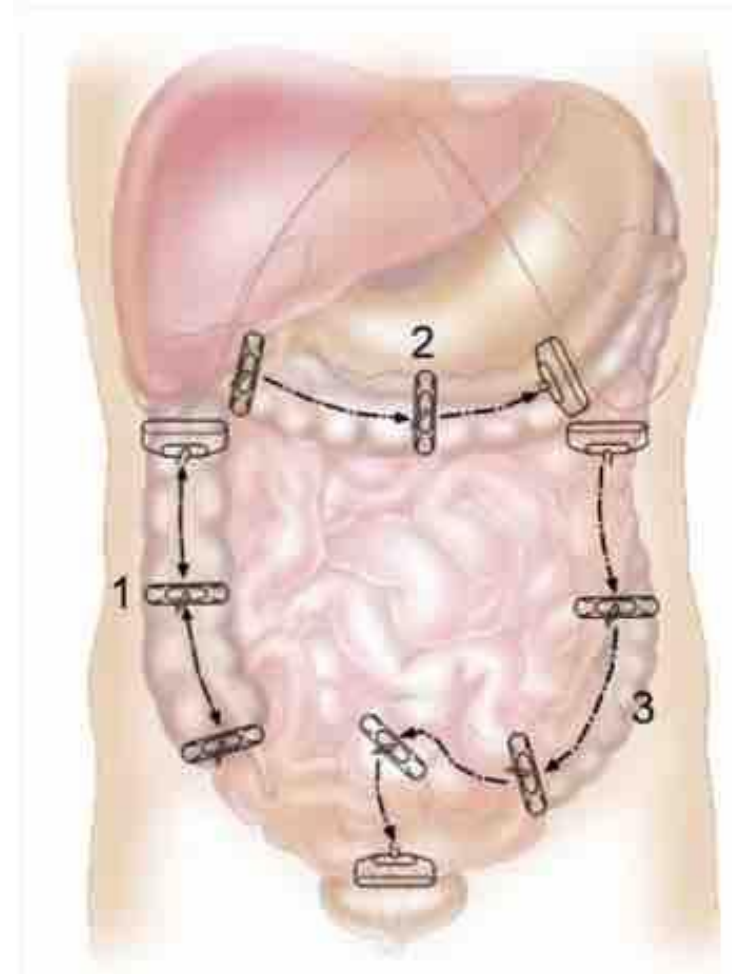
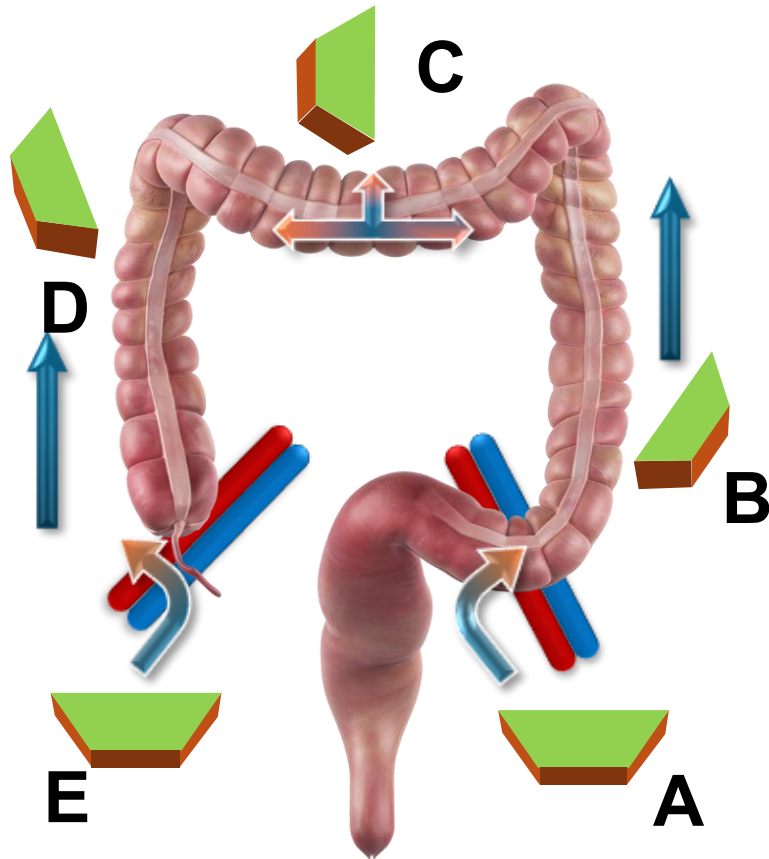
# Examination technique – Systematic

## RECOMMENDATIONS:

10. The scanning of the intestines must involve a systematic approach, LoE 5, GoR C. Strong consensus 12/12

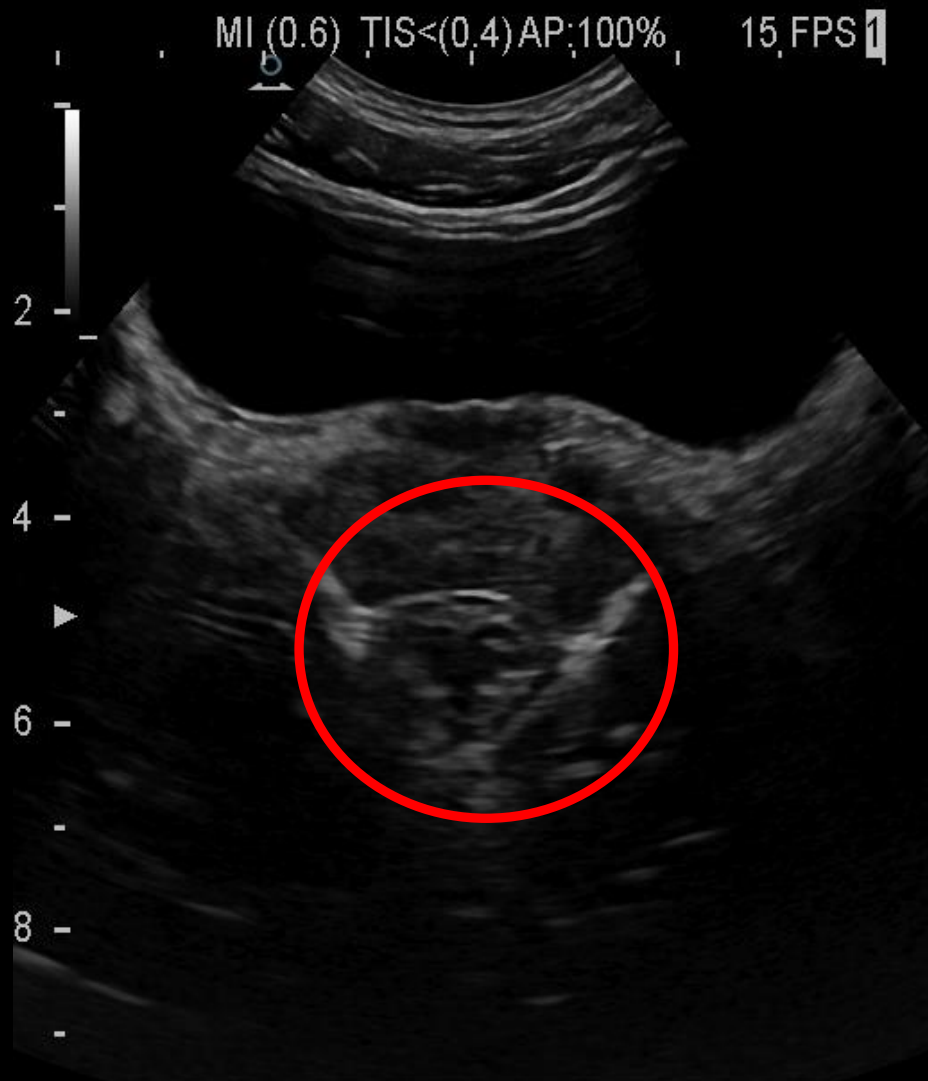
Rectum → Sigmoid → Decending → Transverse → Ascending → Ceacum  
→ Terminal Ileum  
→ Small bowel

## Colon



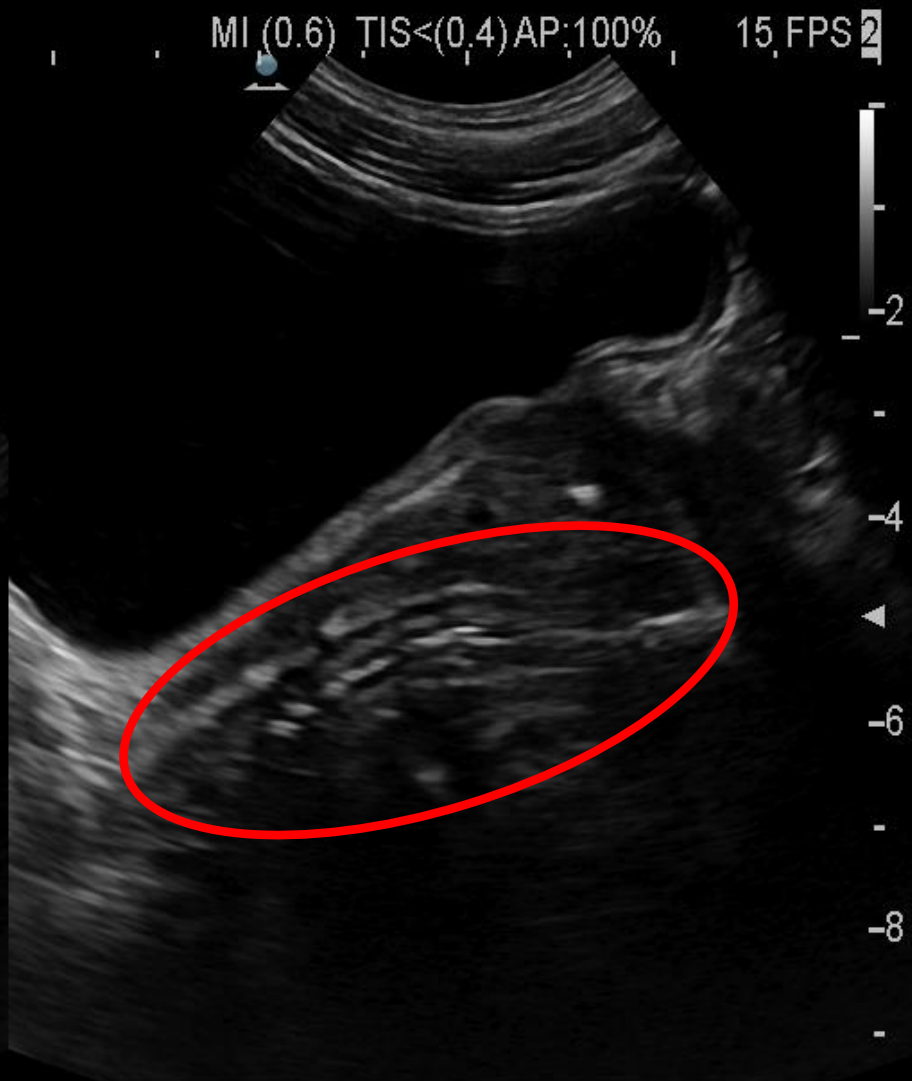


# Rectum



Intestino

Probe:C42

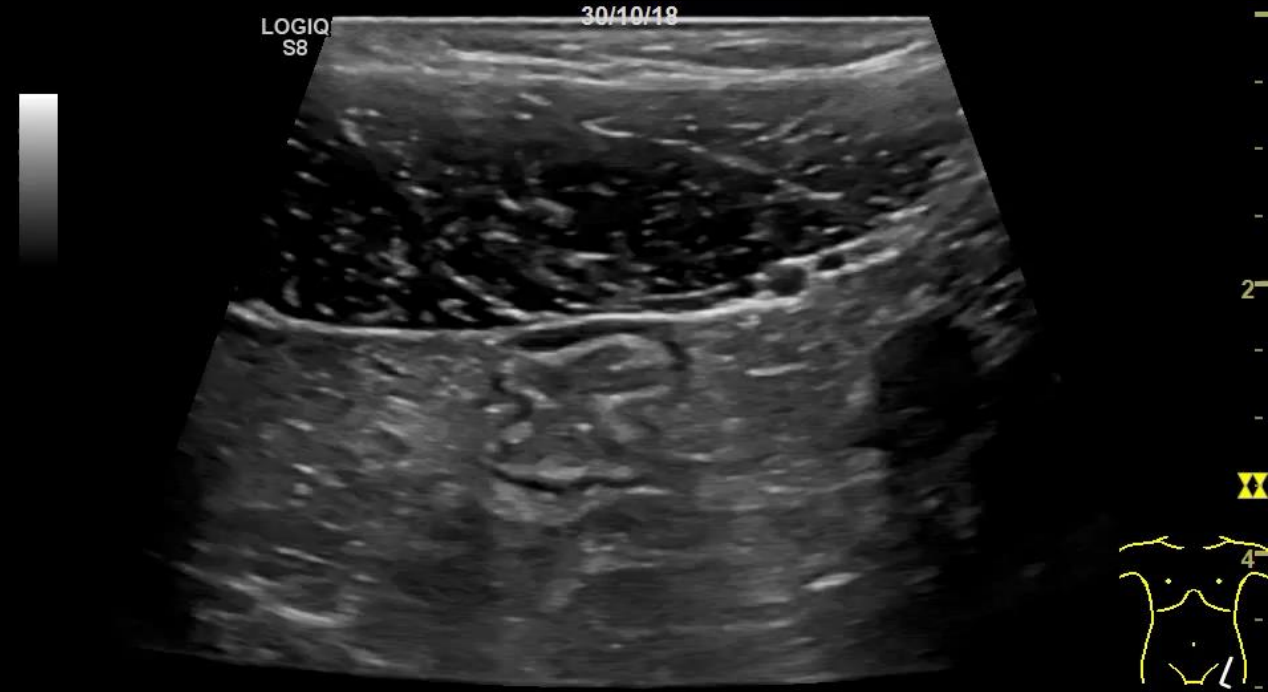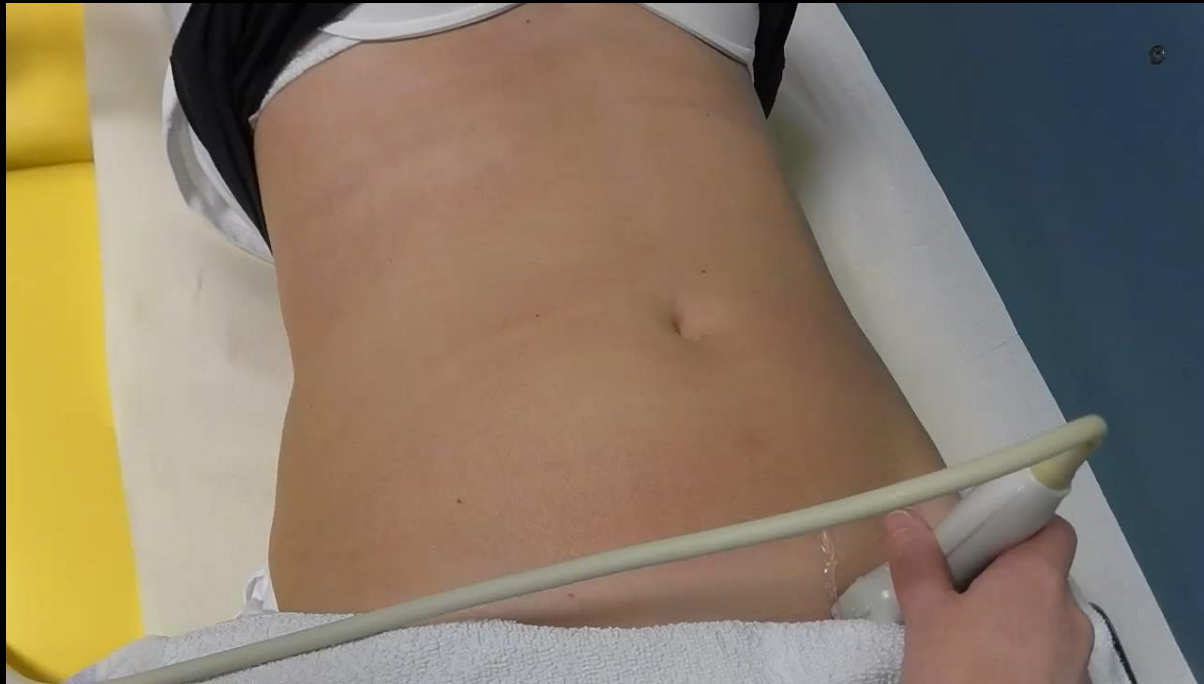


Intestino

Probe:C42



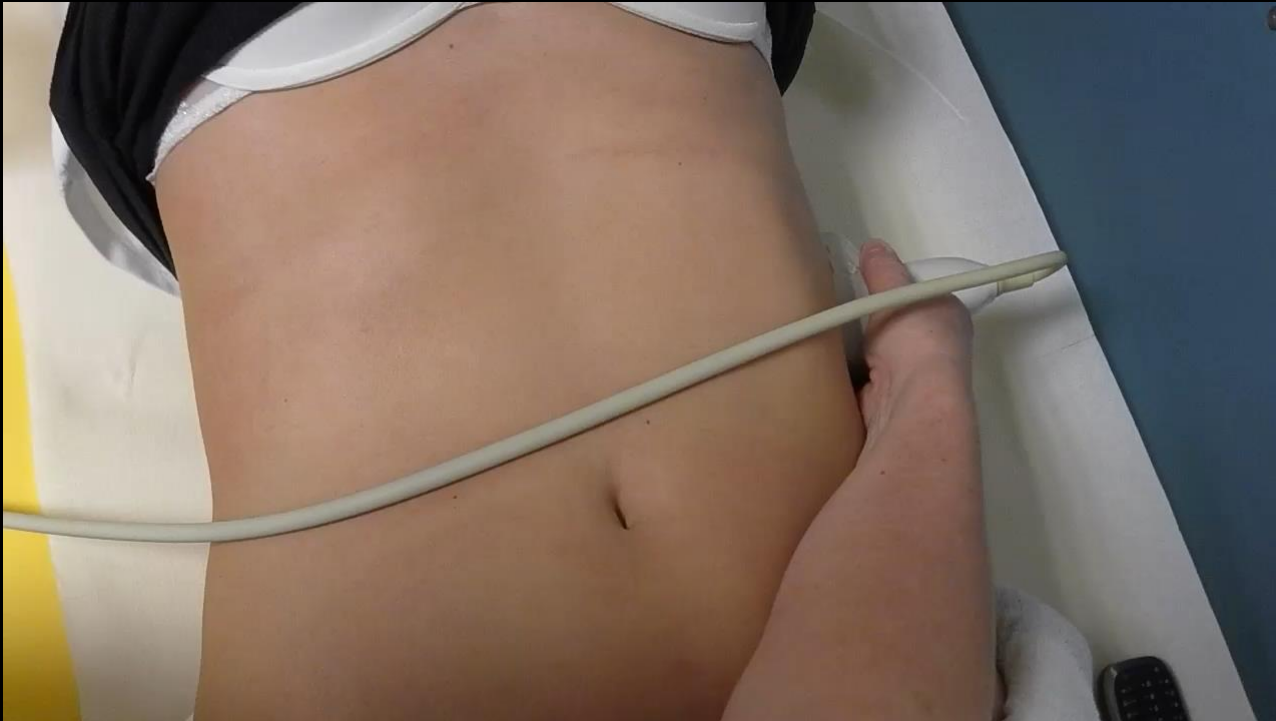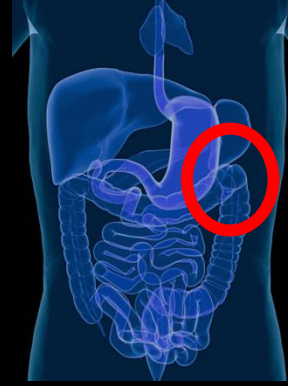# Sigmoid Colon





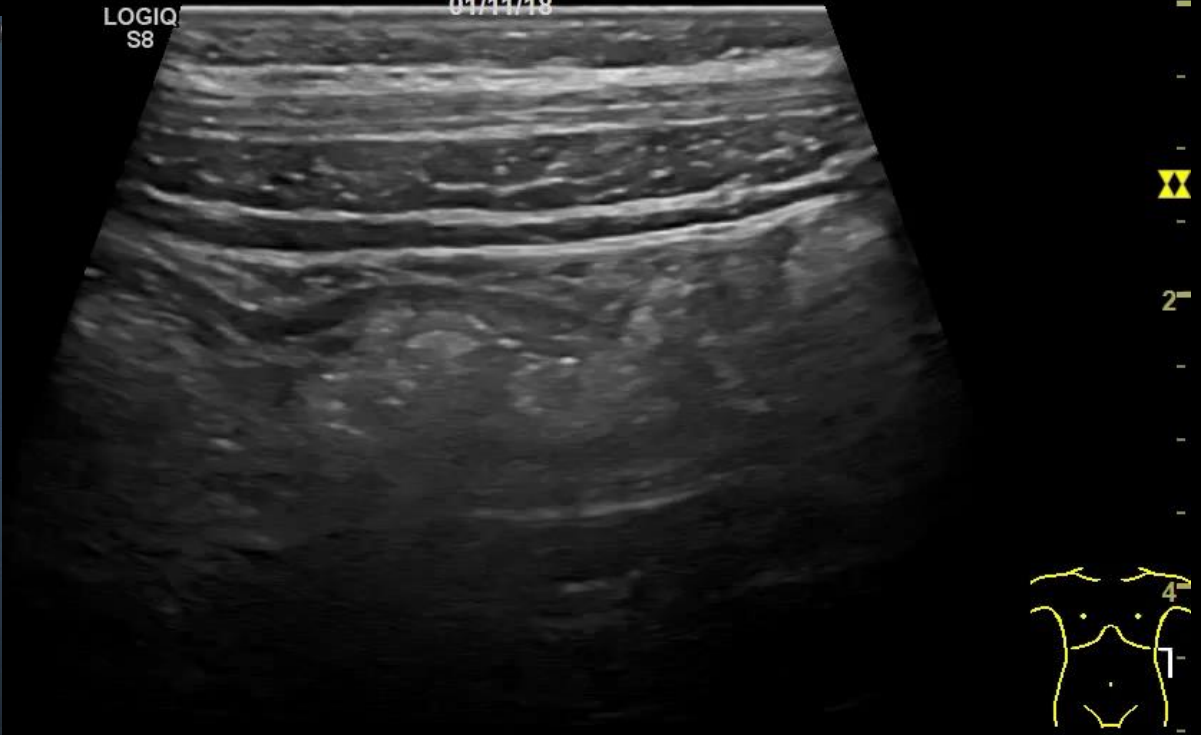


# Descending colon

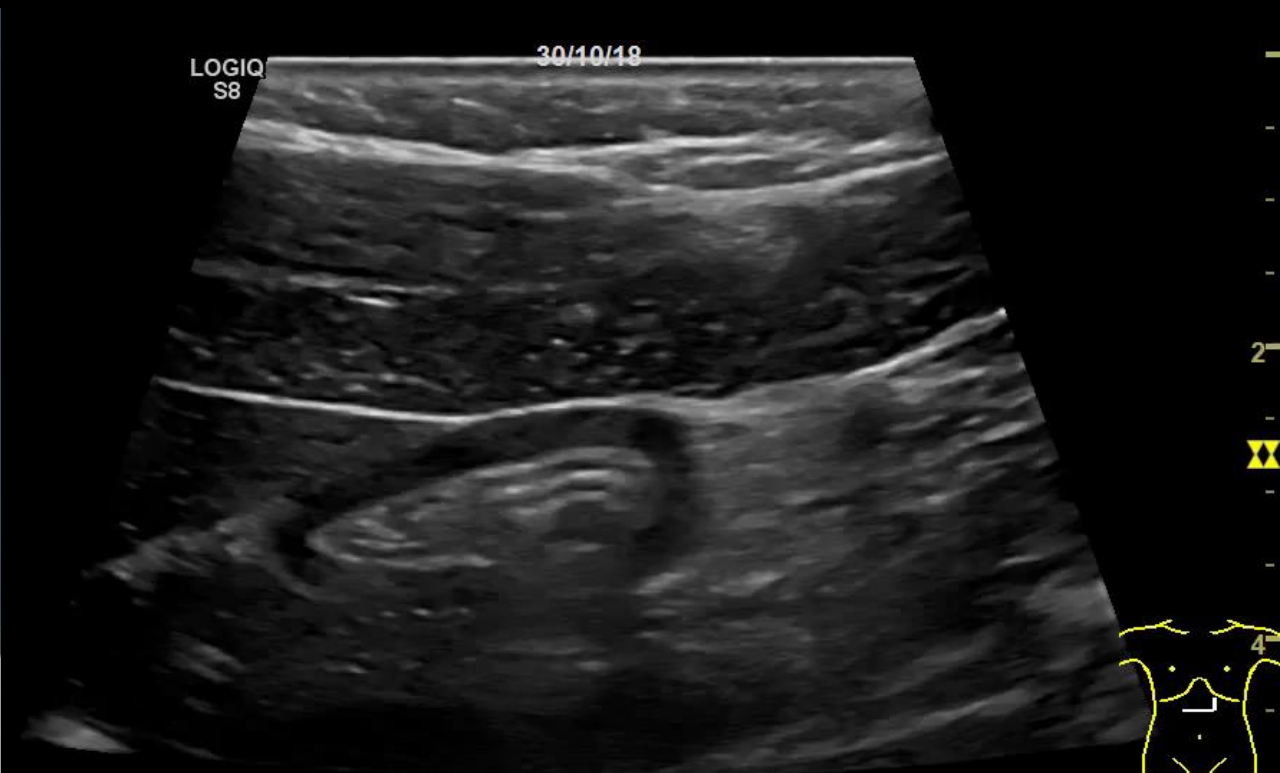
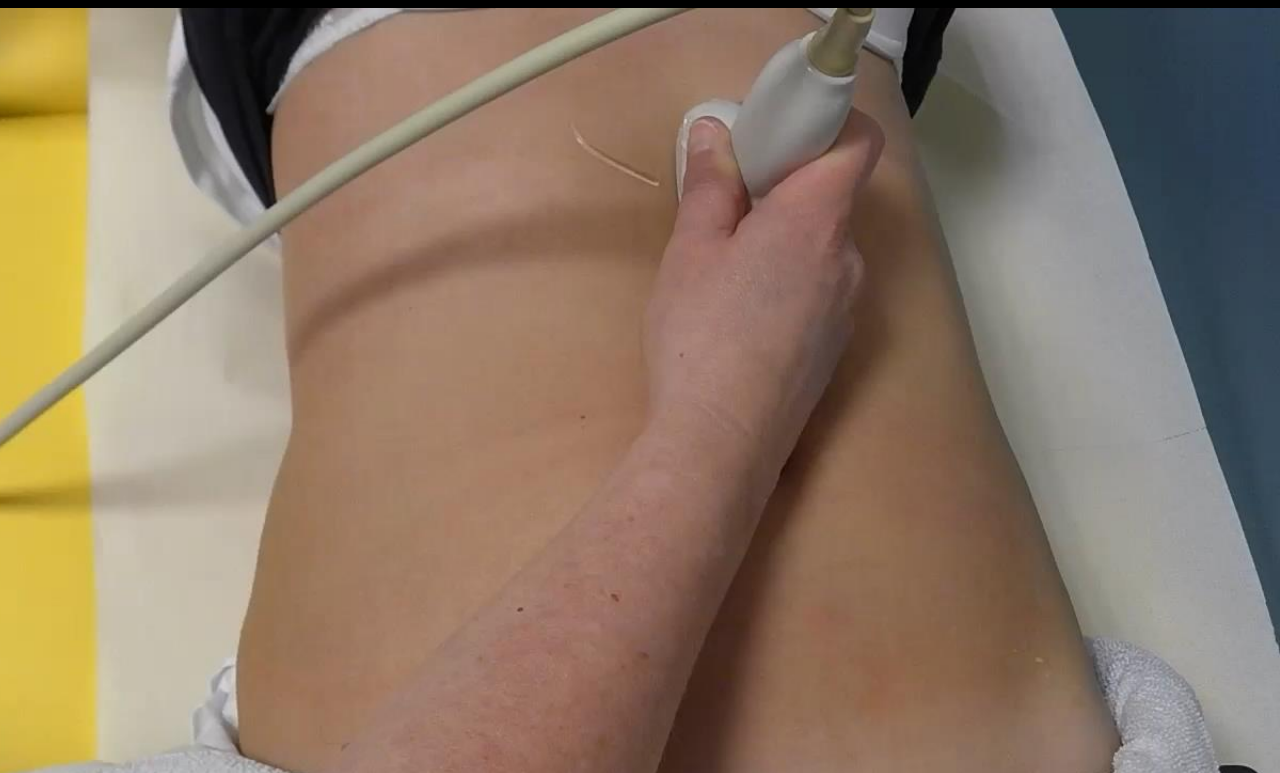

LOGIQ  
S8

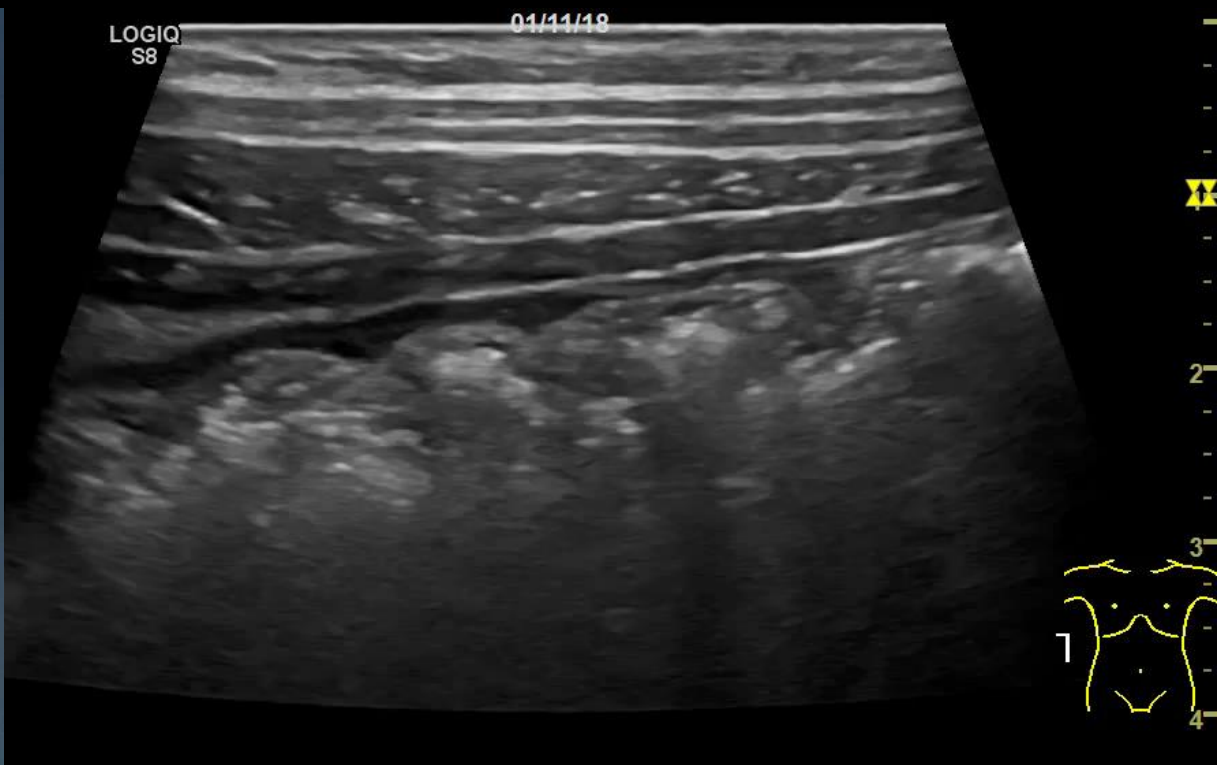
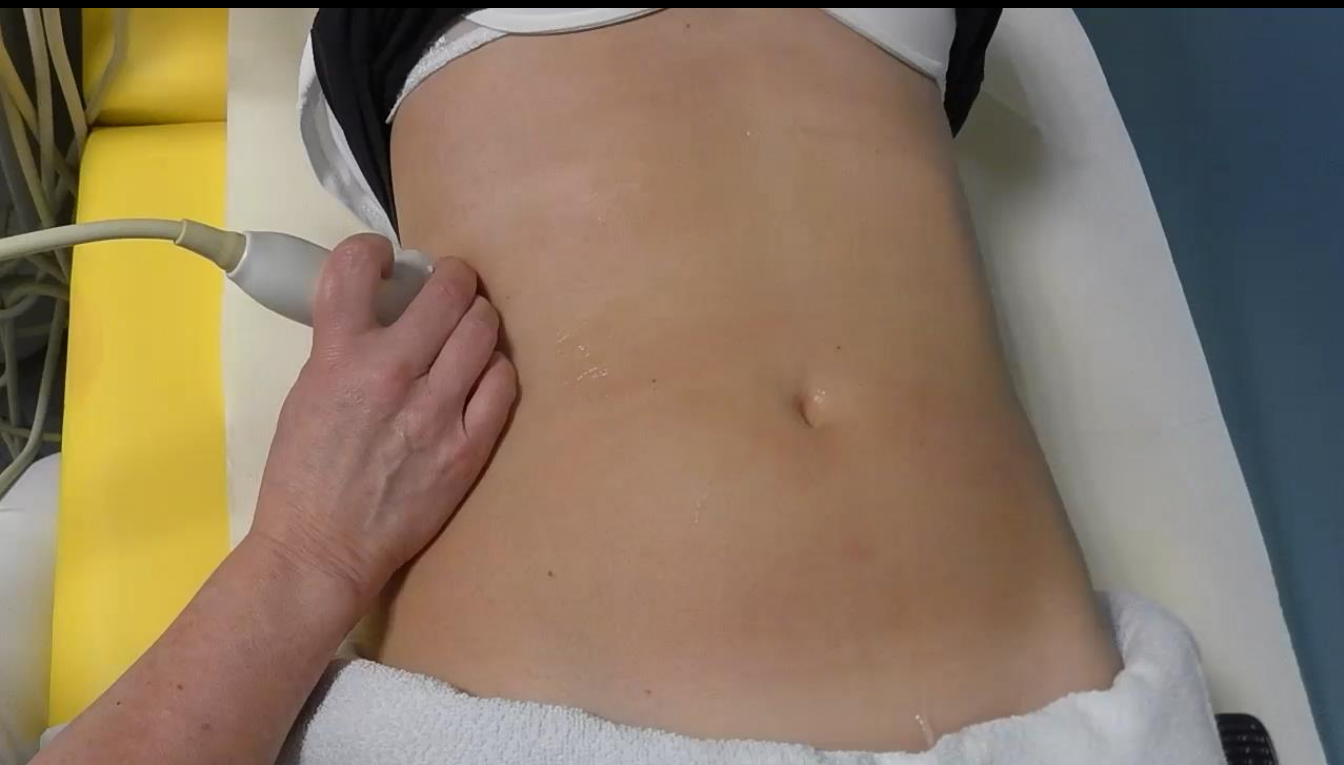01/11/18



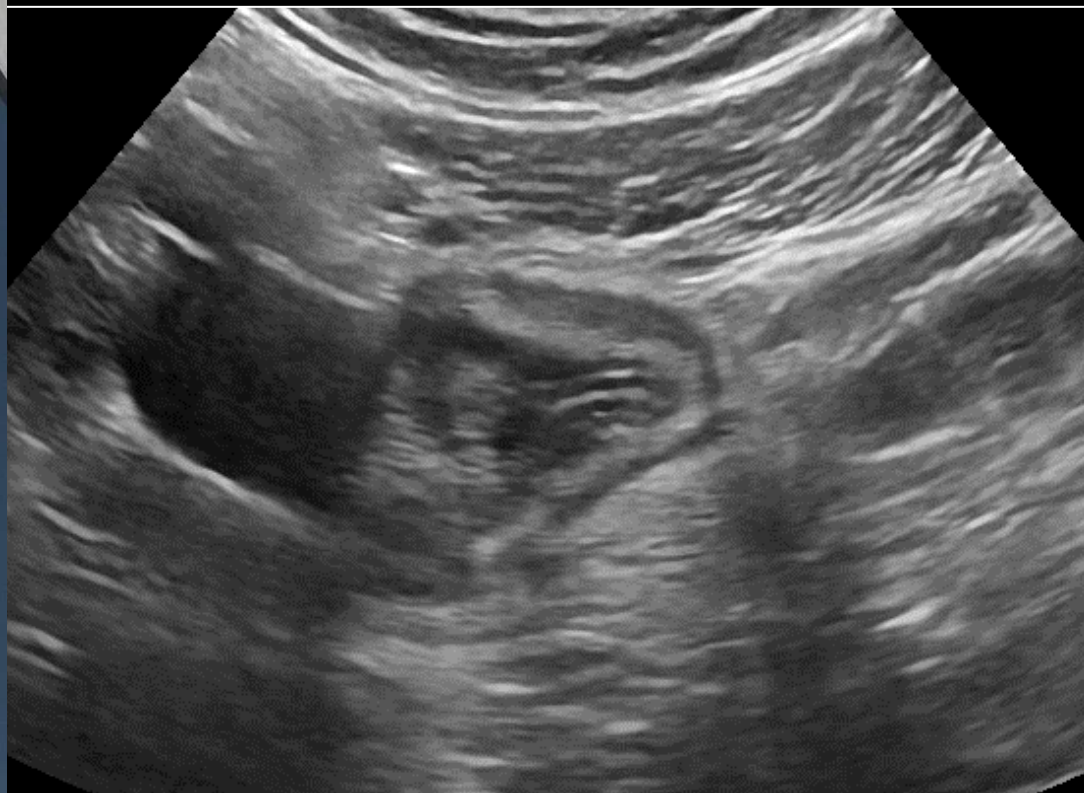
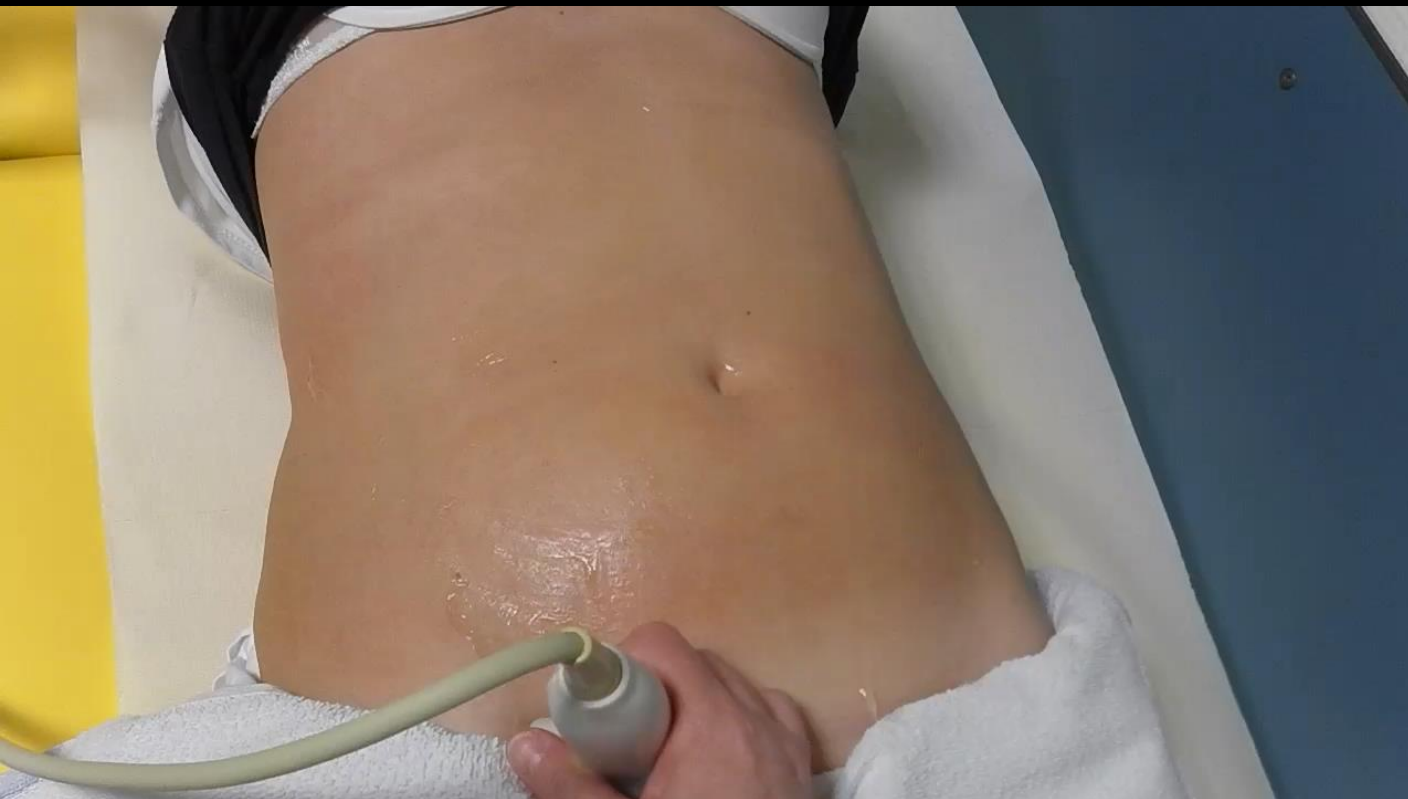# Transverse colon



# Ascending colon



# Terminal ileum

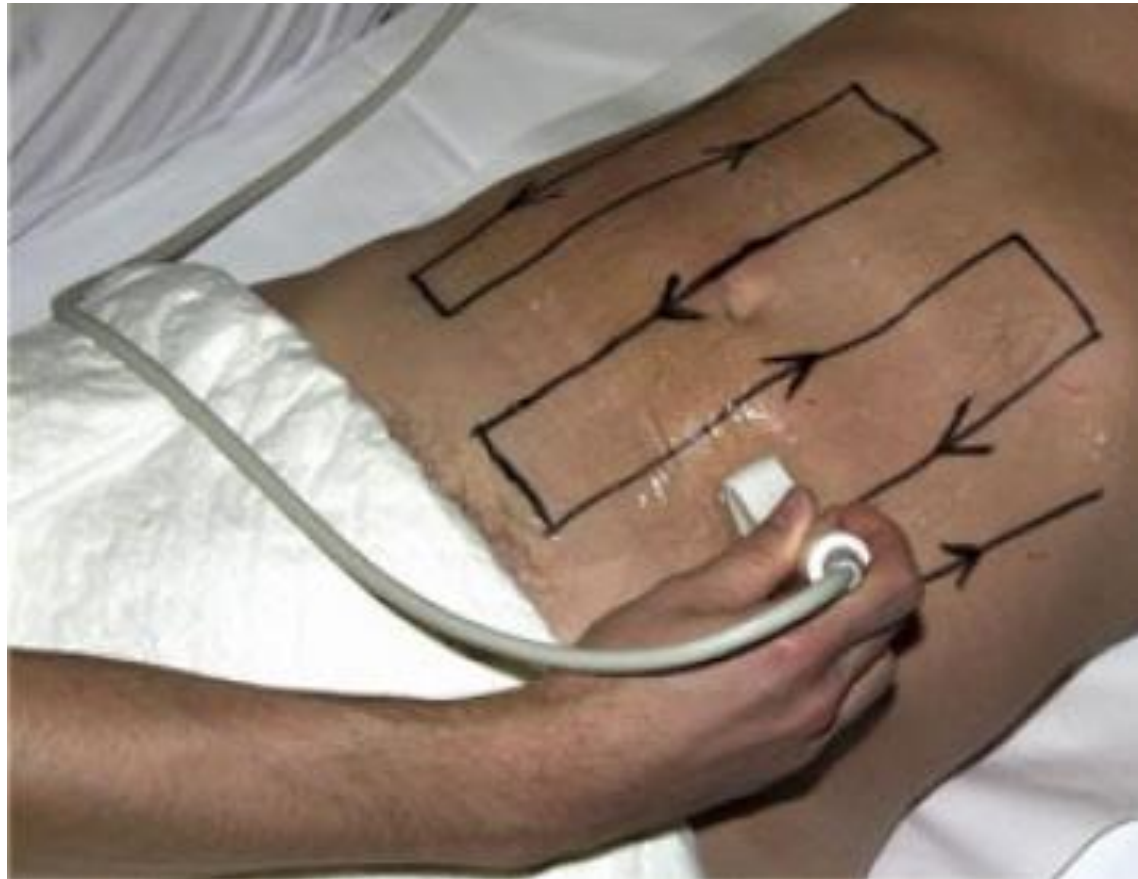


# Examination technique

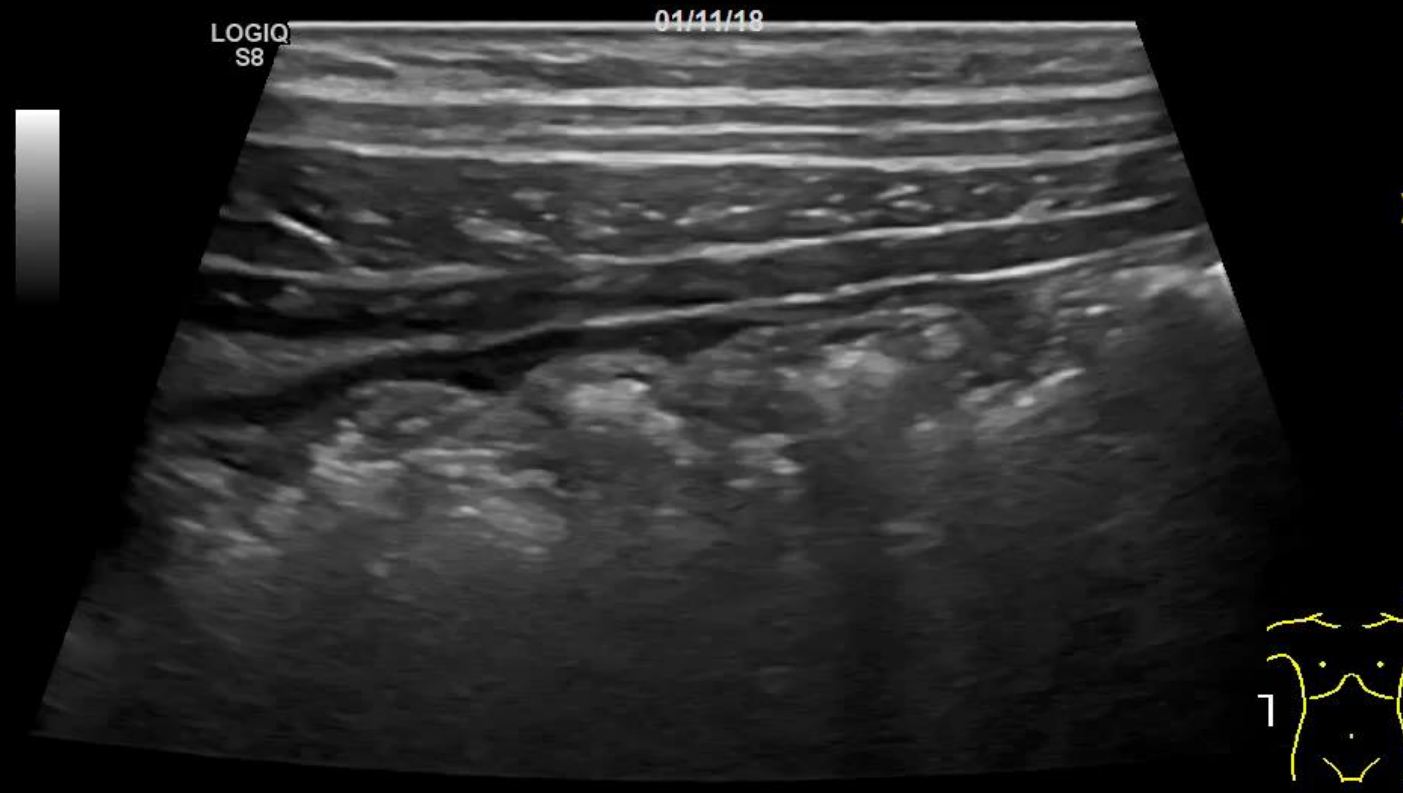
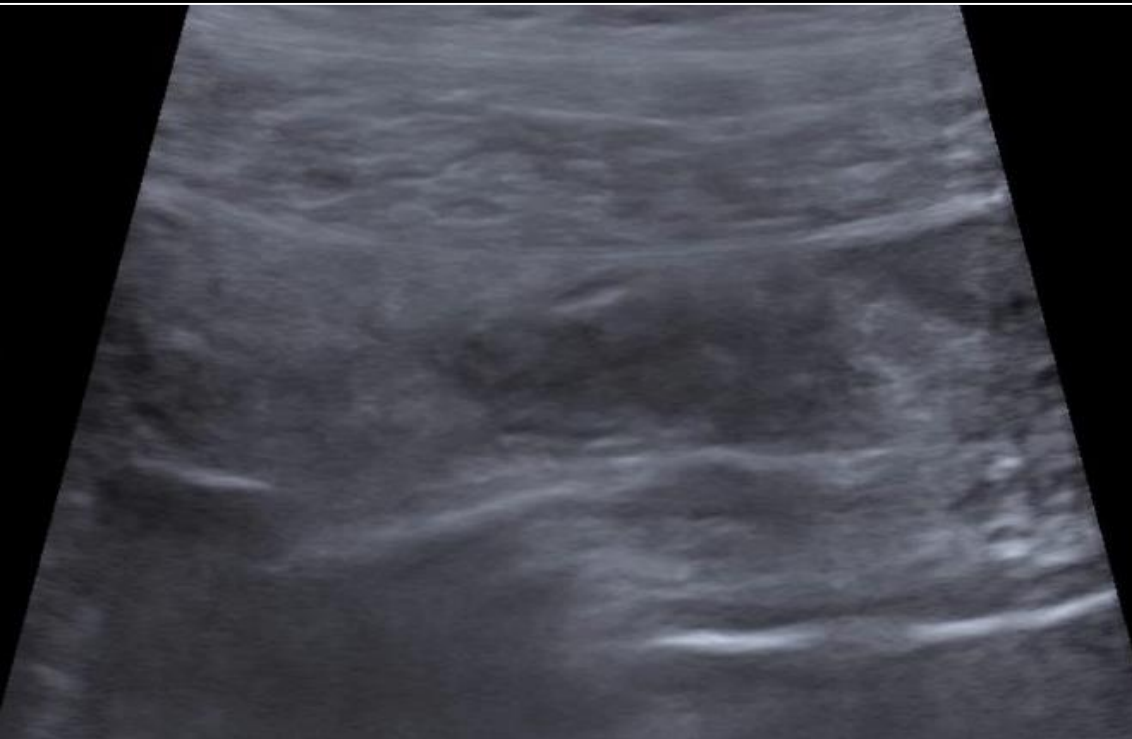
## Systematic approach


- Small bowel

*“mowing the lawn” technique*



# Differentiation between small and large bowel on IUS





# Take home messages

- ✓ Preparation: none
- ✓ Probe 5-8 MHz
- ✓ orientation
- ✓ know what to look for
- ✓ anatomical landmarks
- ✓ ultrasound scan plans
- ✓ systematic approach



Thank you

