international bowel
ULTRASOUND GROUP

How to Perform Intestinal Ultrasound (IUS)

Katherine Falloon, MD

Assistant Professor, Co-Director Intestinal Ultrasound Program

Cleveland Clinic Foundation

Relevant Disclosures

Katherine Falloon, MD:
Advisory Board –Janssen, Abbvie
Speaker Fees: MD Education, Takeda
Research Support – Pfizer, Crohn's and Colitis Foundation

Thank you IBUS for providing these slides

international bowel
ULTRASOUND GROUP

Prepare the machine and yourself

- Know the indication, clinical setting and patient history
- Clean hands/probe (No alcoholic solutions)
- Position yourself on the right side of the patient
- Cord does not belong on the floor or around your neck
- Probe in right hand
- Left hand on buttons

Is fasting always required?

1. Always required
2. Not required
3. Preferred for motility assessment

international bowel
ULTRASOUND GROUP

Preparation (patient)

Fasting

- not necessary
- >4 h → reduce amount of food and air in the small bowel
- >6 h → recommended before assessing splanchnic blood flow and GI motility

Nylund K et al. EFSUMB Recommendations and Guidelines for Gastrointestinal Ultrasound, Ultraschall Med 2017

international bowel
ULTRASOUND GROUP

Prepare the machine – Insert patient's details

- Check patient ID / details
- Save examination when you finish

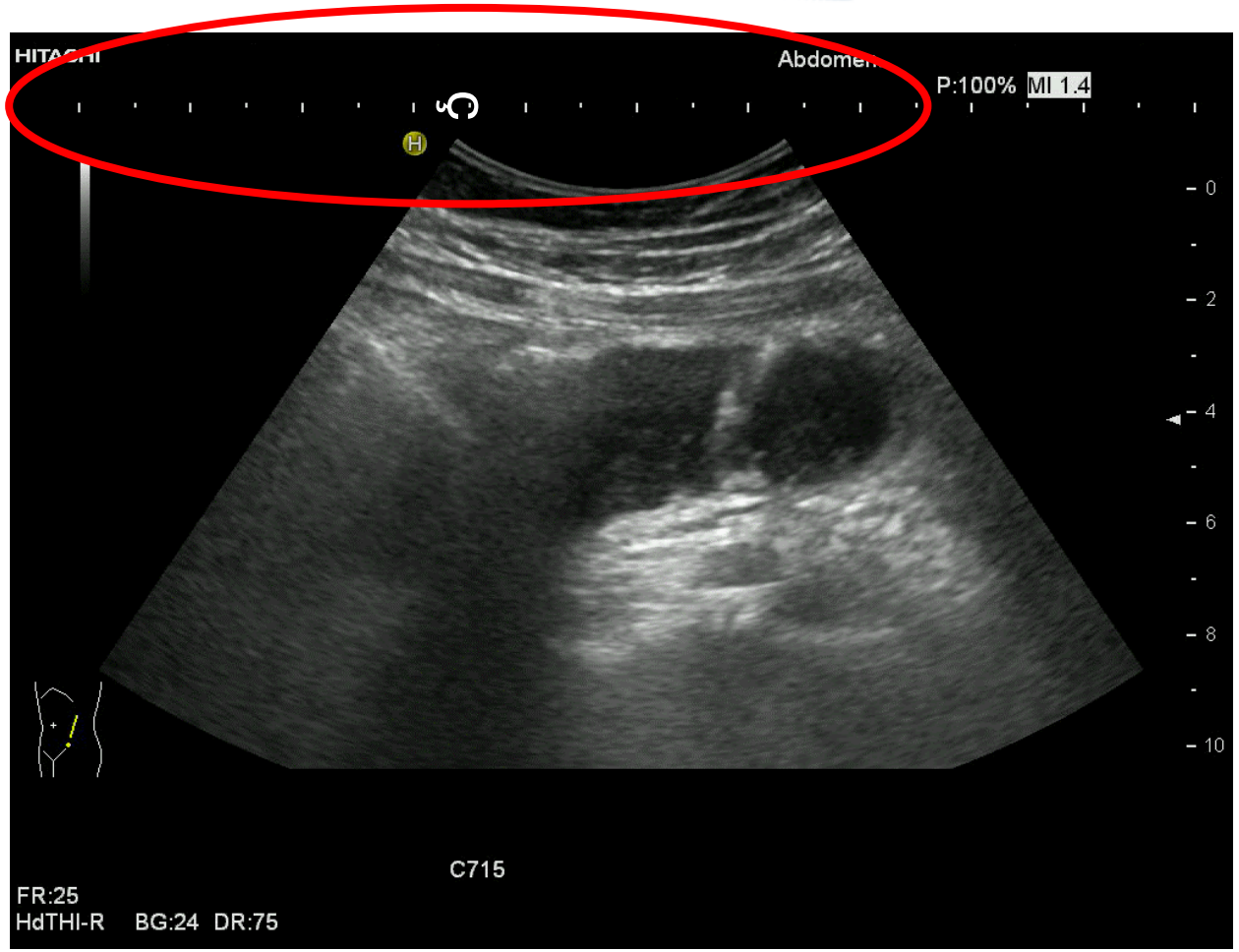

international bowel
ULTRASOUND GROUP

Ultrasound machine

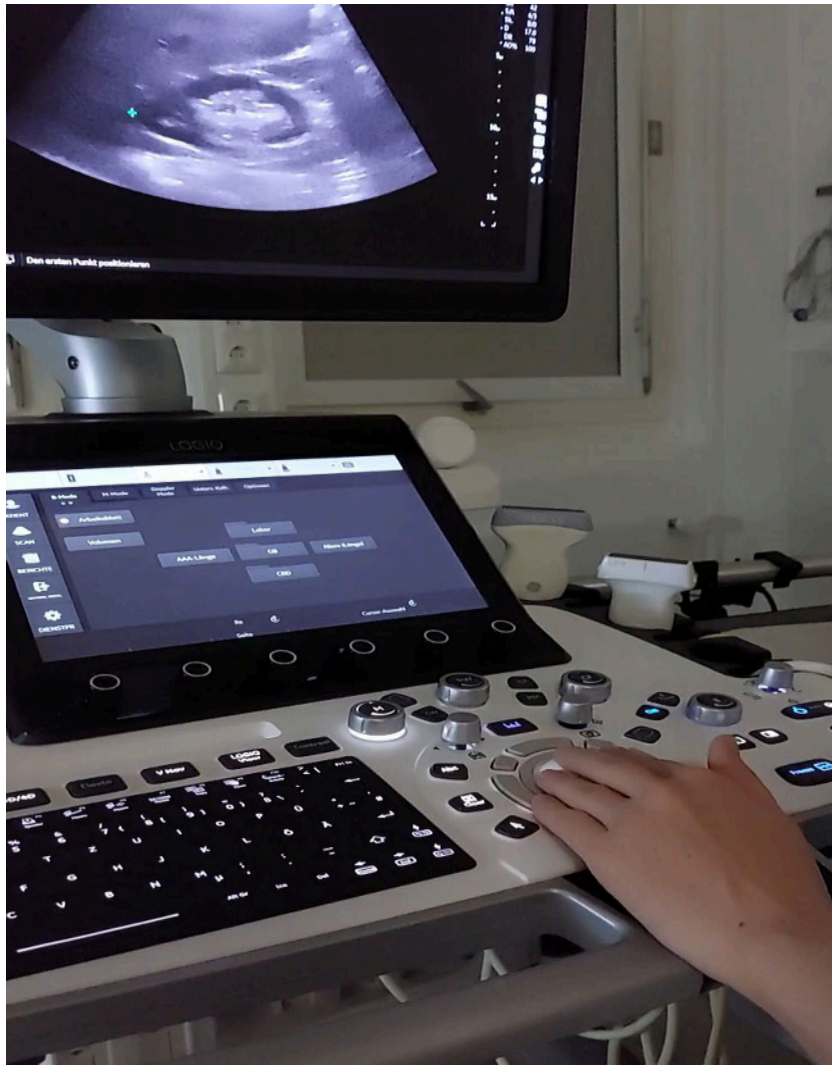

Monitor

Touchscreen

Probes

Control panel

Gel

international bowel
ULTRASOUND GROUP

Ultrasound probes

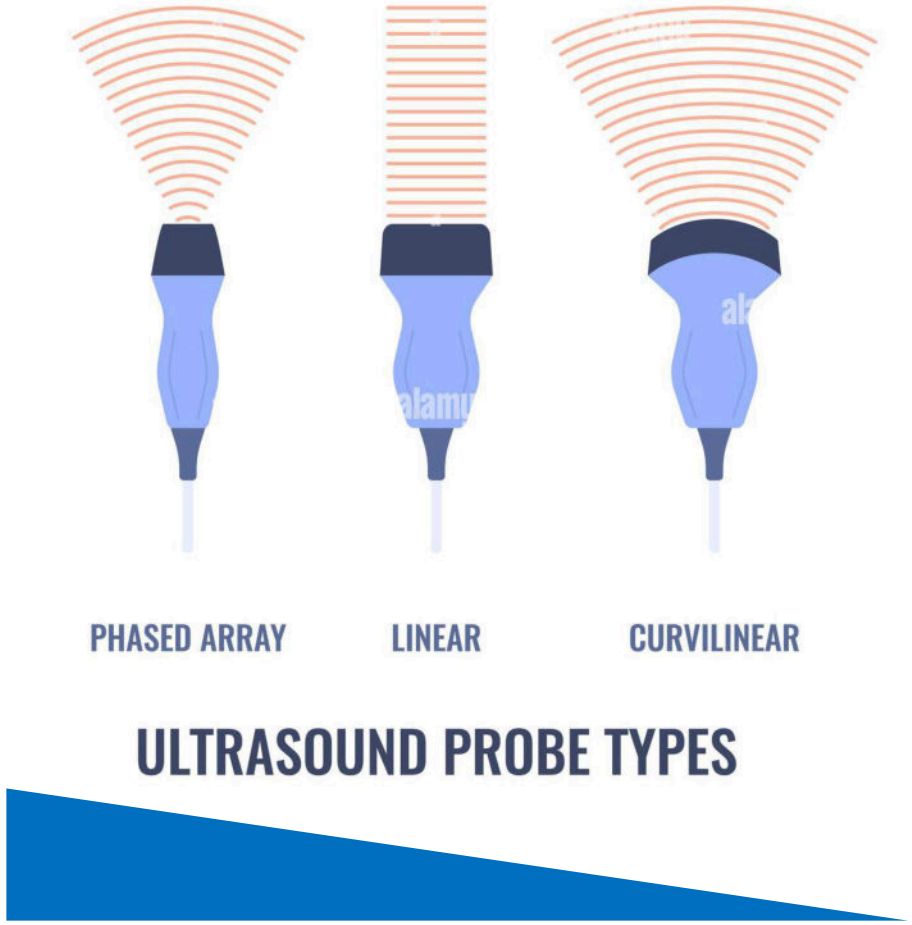

Frequency

Linear probe – which is correct

1. Has low frequency
2. Has high frequency
3. Needed for overview of the bowel
4. Isn't used in IUS

international bowel ULTRASOUND GROUP

Properties of the different probes

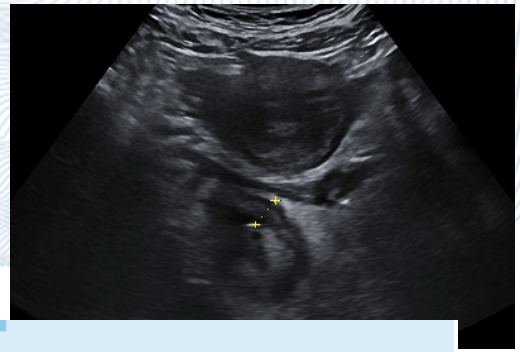

Low frequency: 1-6 MHz, overview, more depth, less resolution

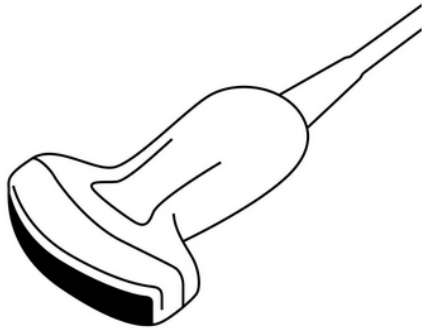

curved array for a larger field, de

pathology

RECOMMENDATIONS:

1. For a complete examination of the bowel both a low and high resolution probe are needed, LoE 5, GoR C, Strong consensus 13/13
2. A probe with a frequency above 5 MHz should be used when measuring wall thickness, LoE 4, GoR B, Strong consensus 13/13

Nylund K et al. EFSUMB Recommendations and Guidelines for Gastrointestinal Ultrasound, Ultraschall Med 2017

High frequency: > 5MHz (5-10 MHz), only surface accessible (8-10 cm depth penetration), high resolution, detailed examination (discrimination of stratification of the bowel wall)

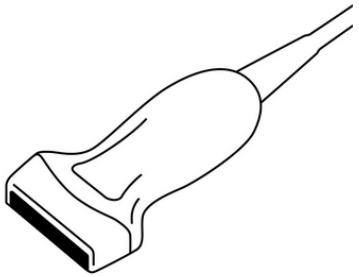

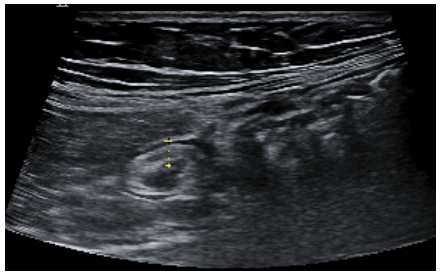

international bowel
ULTRASOUND GROUP

Ultrasound technique

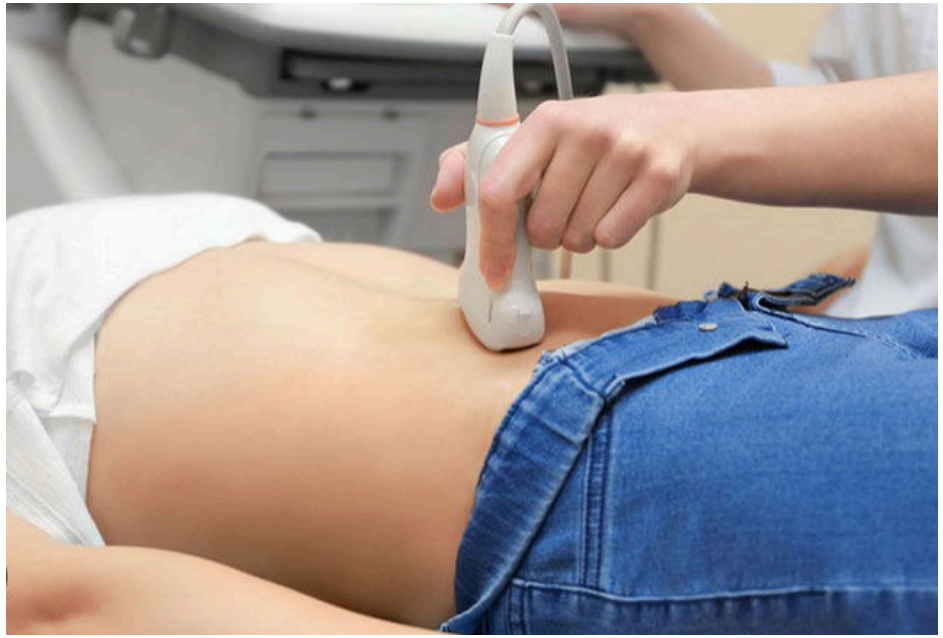

international bowel
ULTRASOUND GROUP

Prepare the patient

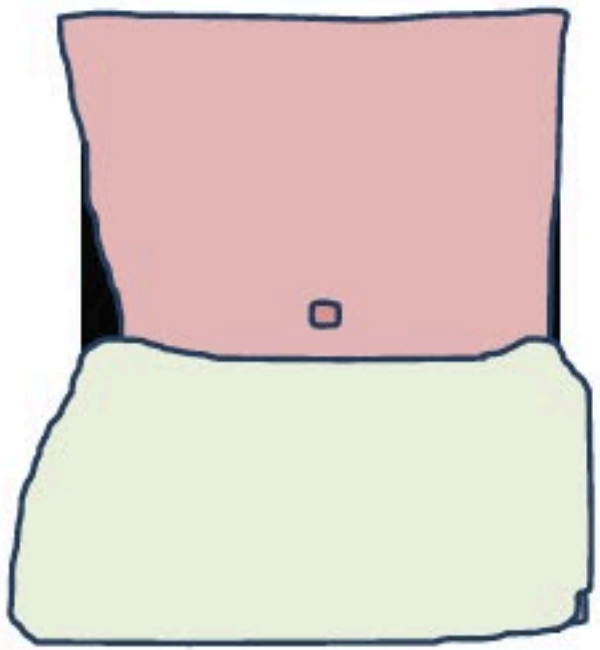

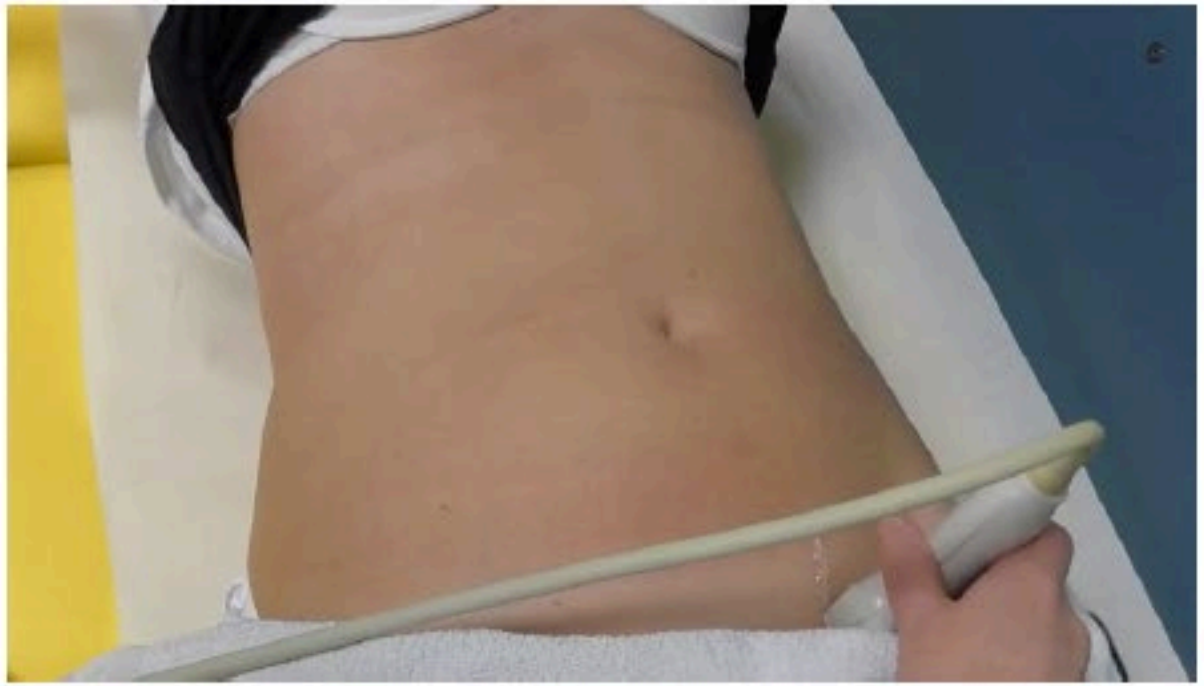

international bowel
ULTRASOUND GROUP

- Expose abdominal area adequately
- Water-based ultrasound gel
- Hold the probe correctly

international bowel
ULTRASOUND GROUP

Ultrasound technique

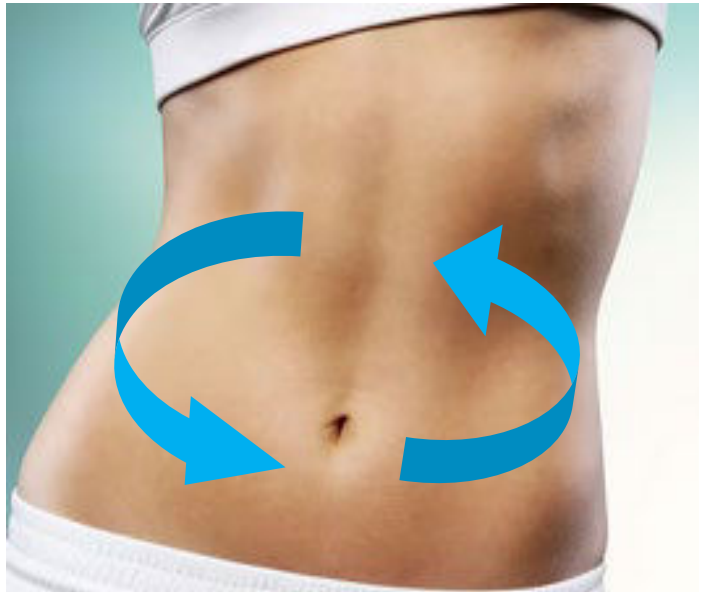

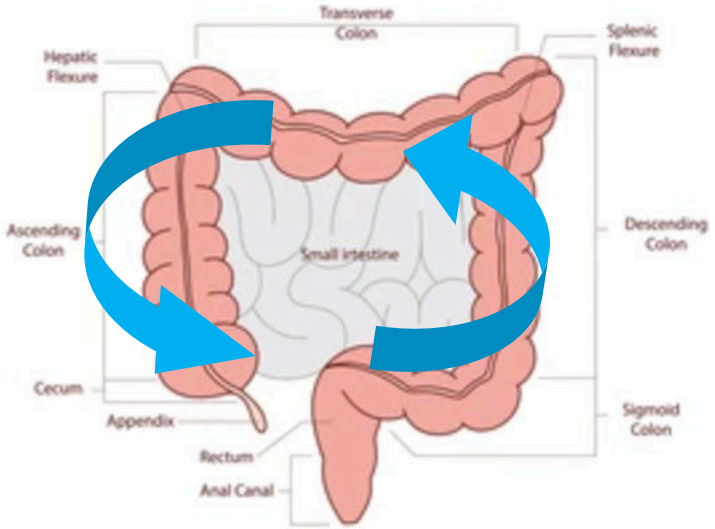

In a segment-wise manner, **all portions** of the bowel are scanned in long and short axes, and images are simultaneously captured to ensure **a continuous assessment**

international bowel
ULTRASOUND GROUP

Scan planes

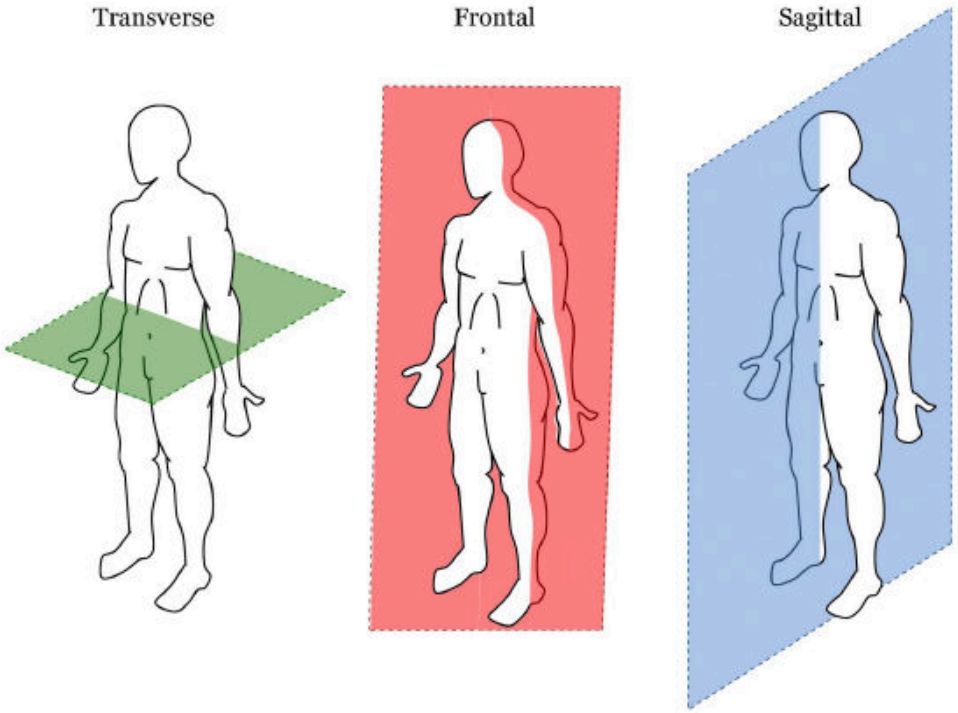

Imaging

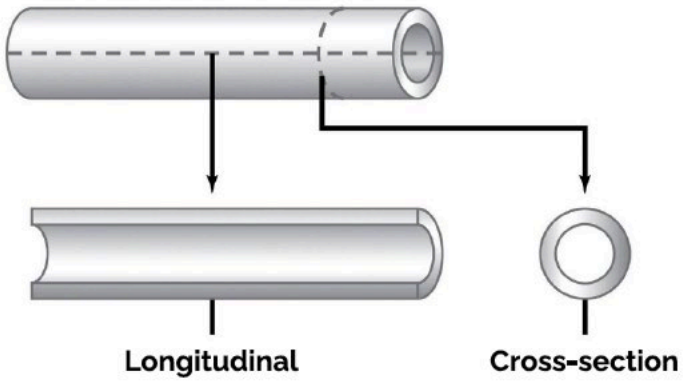

Intestinal ultrasound

international bowel
ULTRASOUND GROUP

Scan planes

Longitudinal

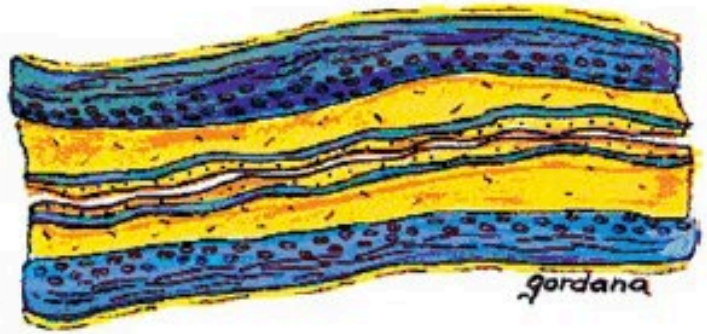

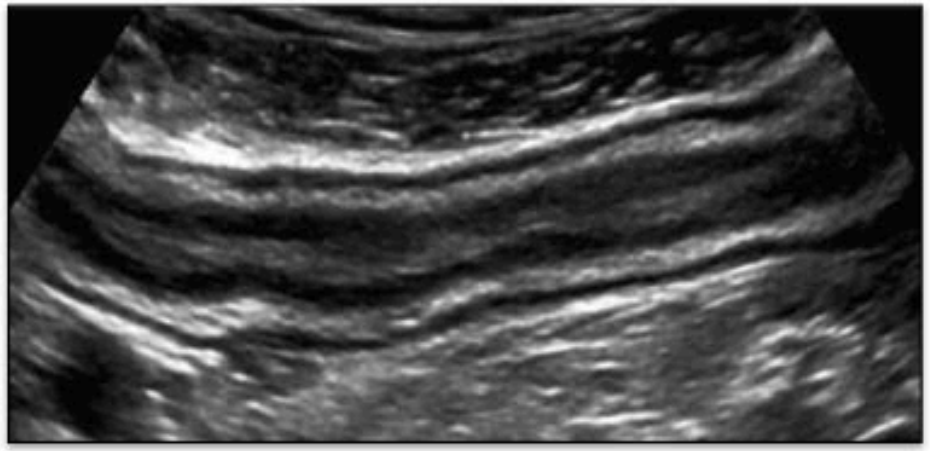

Cross-section



Wilson SR et al. Diagnostic Ultrasound, Mosby 2010; Nylund et al. Scand J Gastroenterol 2008

international bowel
ULTRASOUND GROUP

Probe orientation

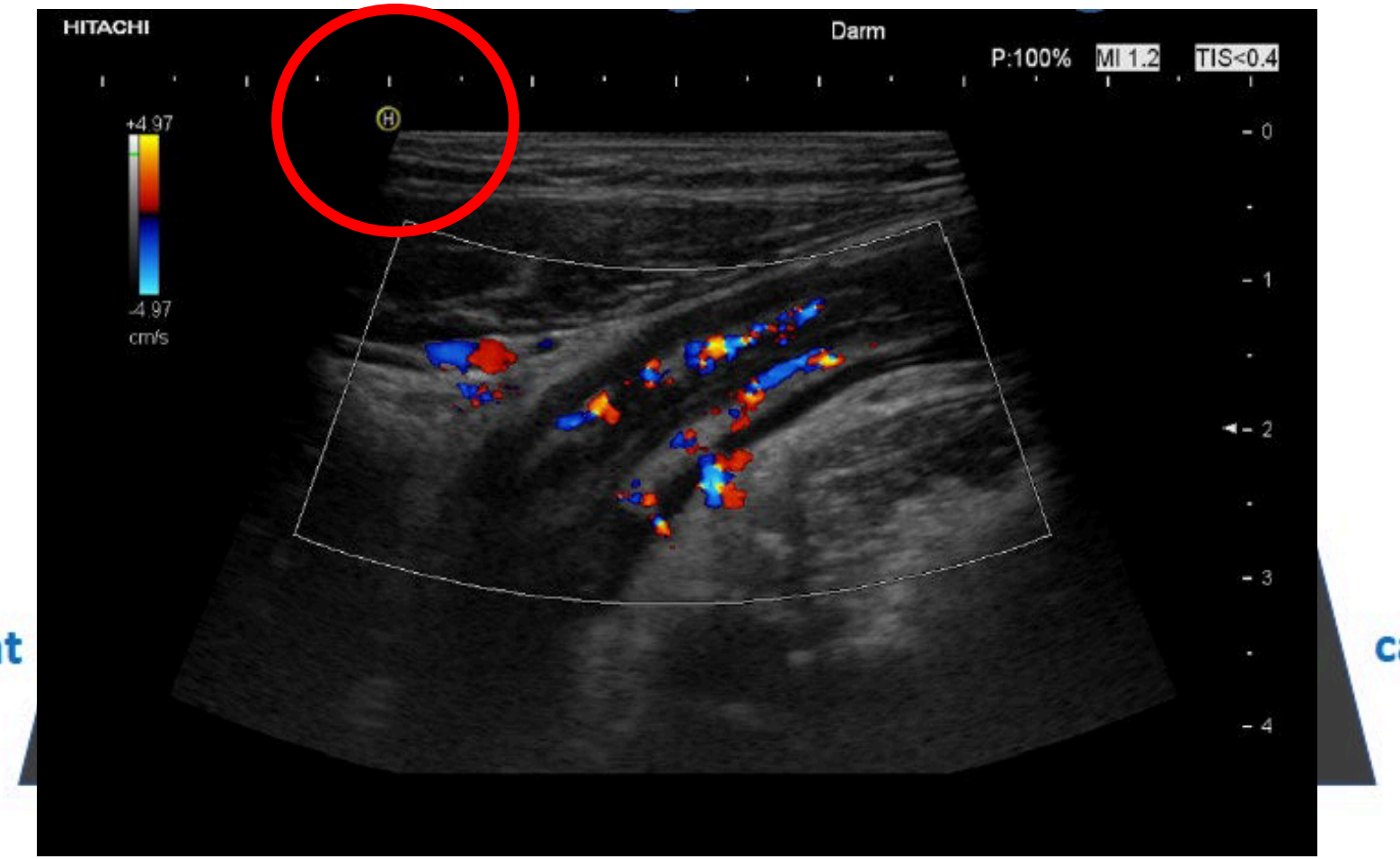

right

caudal

international bowel
ULTRASOUND GROUP

Turning the probe

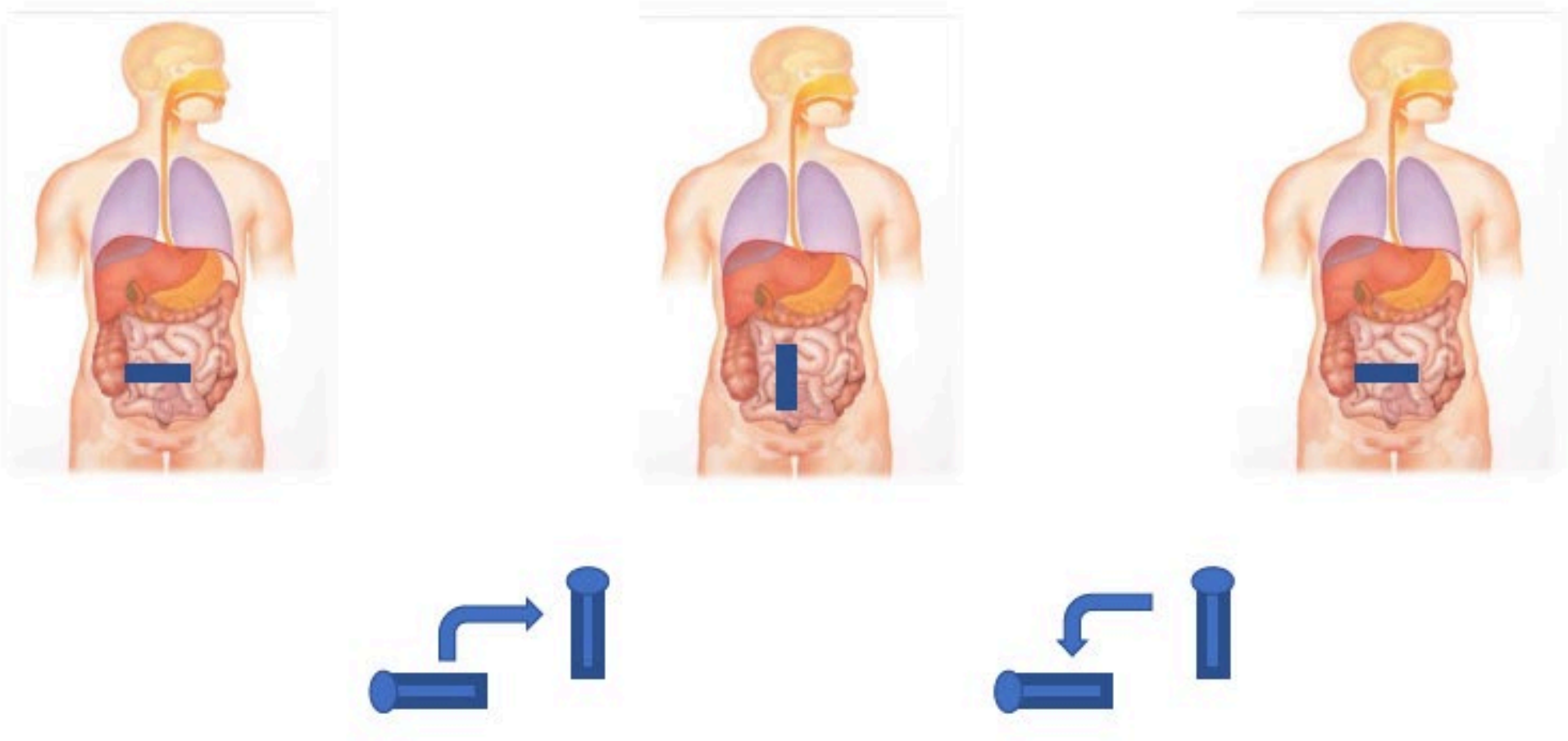

international bowel
ULTRASOUND GROUP

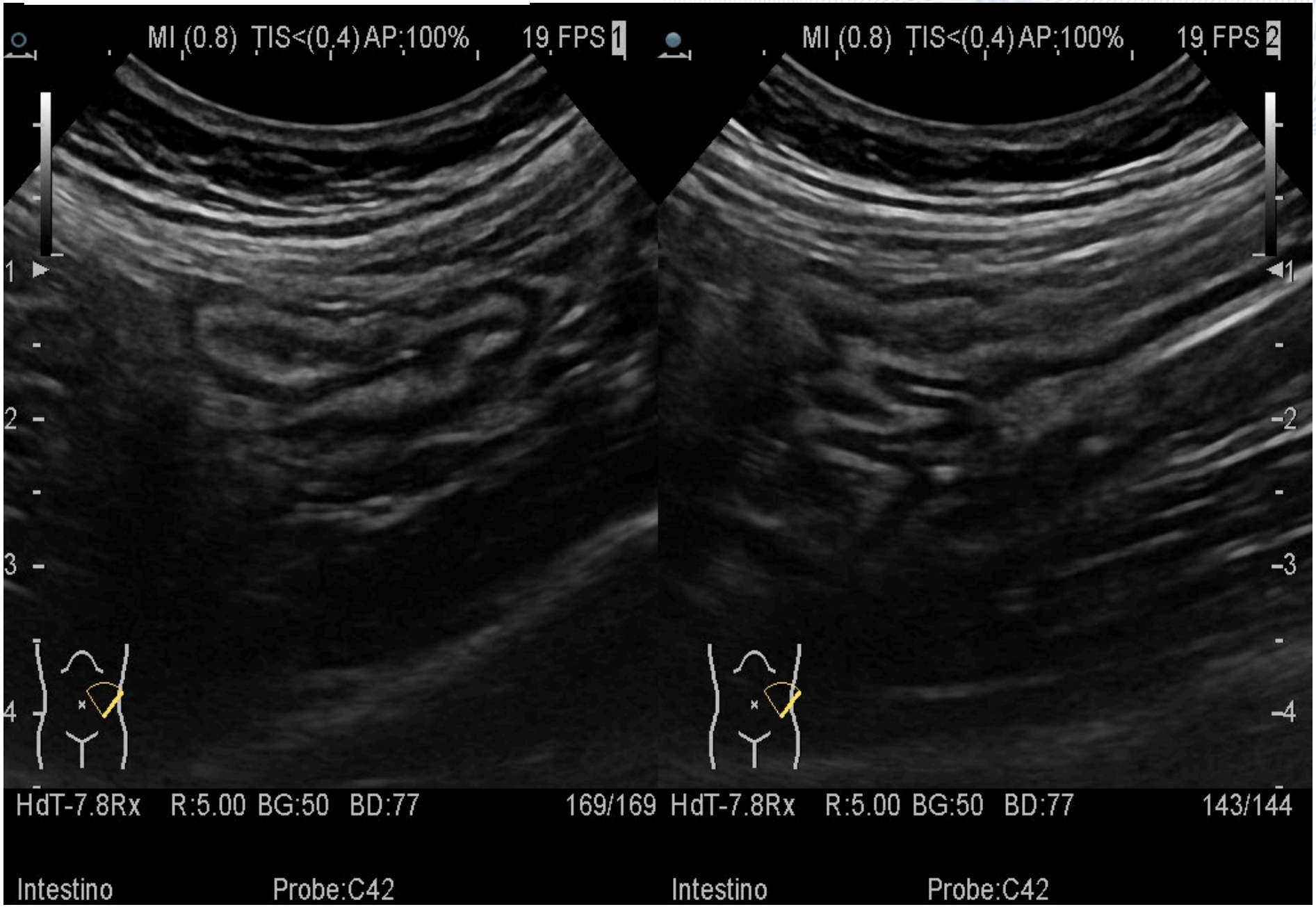

international bowel
ULTRASOUND GROUP

Keep your region of interest in the center

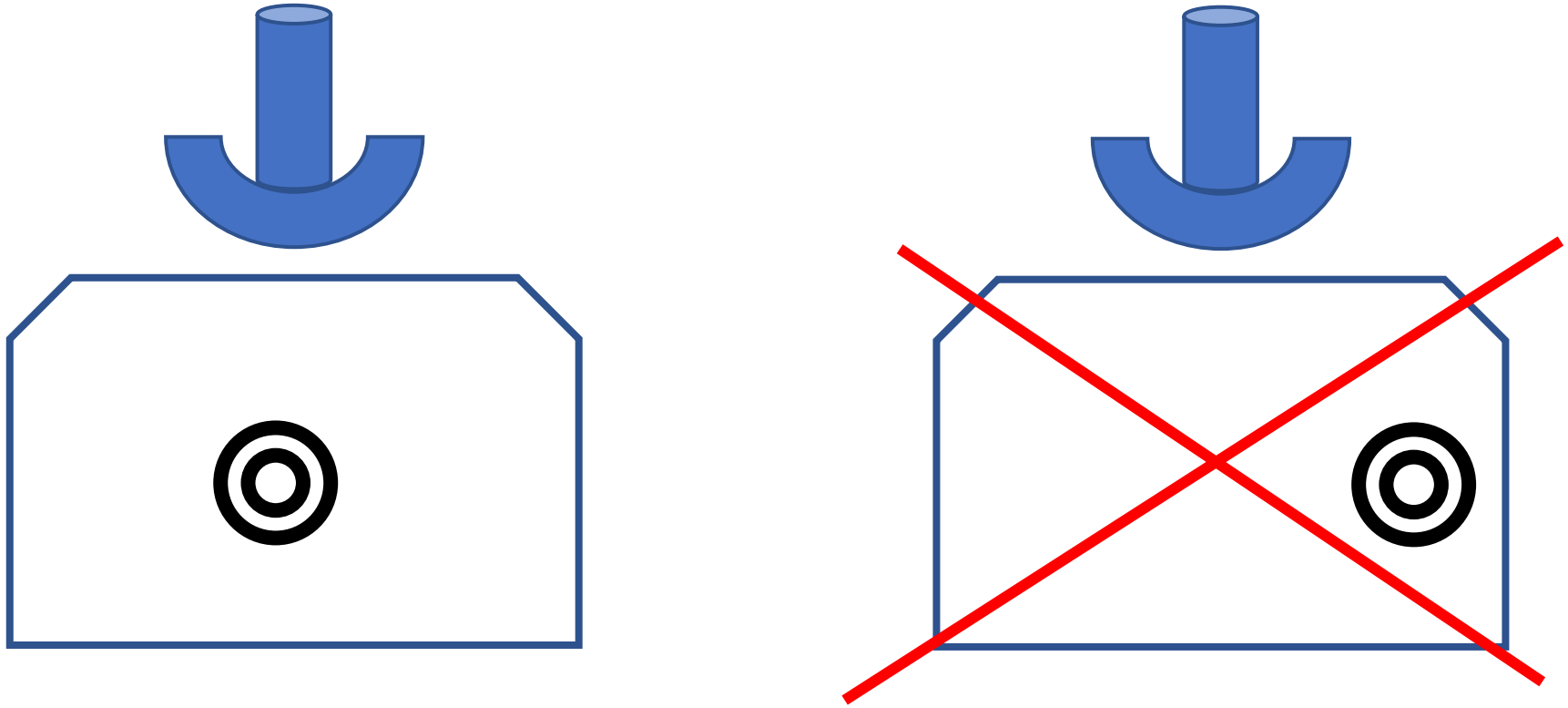

international bowel
ULTRASOUND GROUP

Keep your region of interest in the center

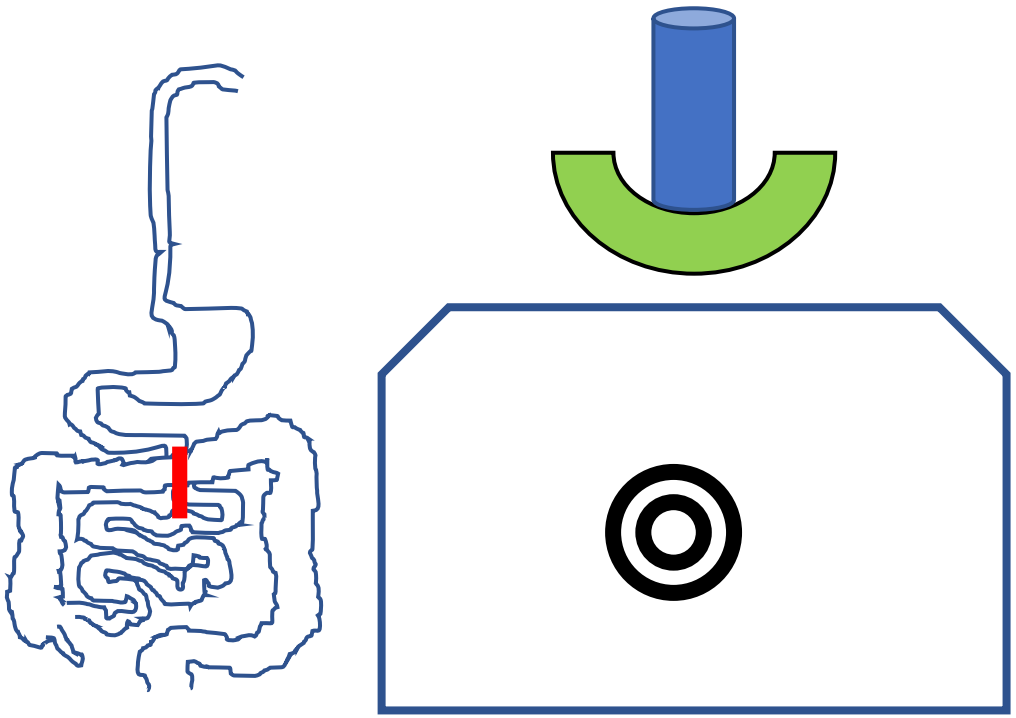

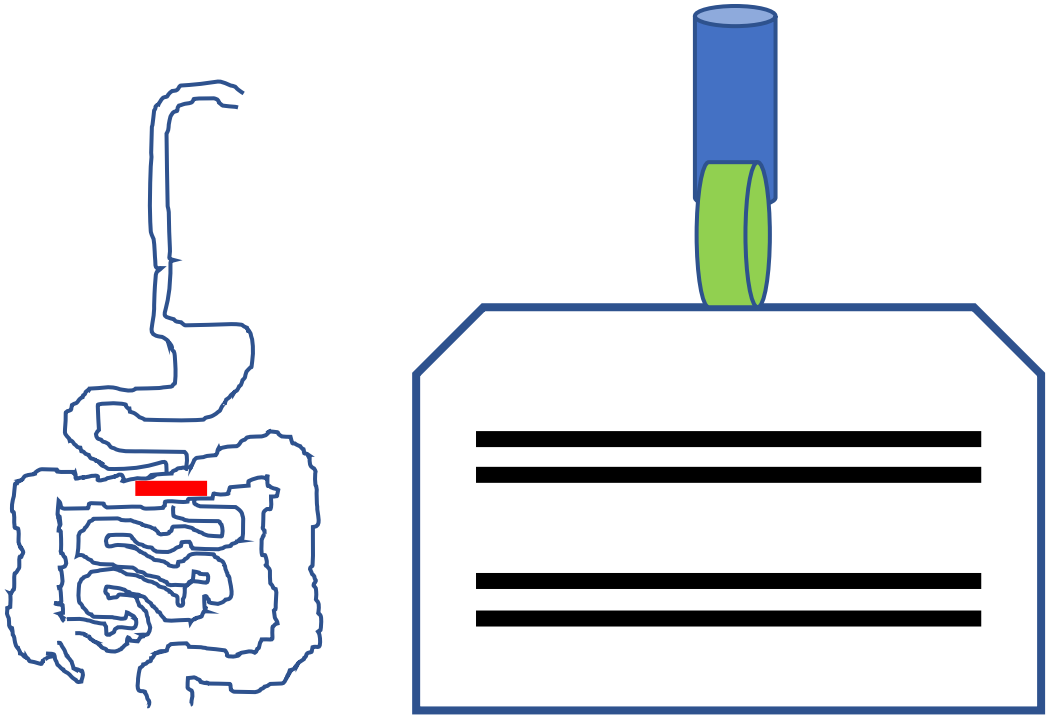

international bowel
ULTRASOUND GROUP

Keep your region of interest in the center

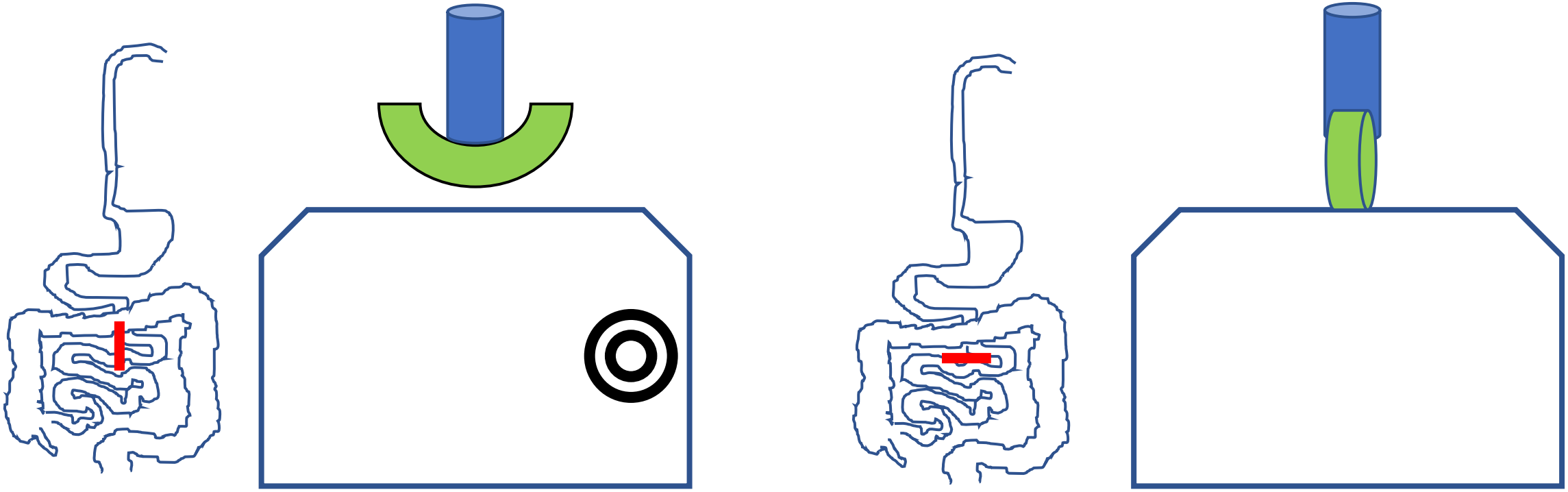

Examination technique

- **Probe movement**

  → set and tilt, not chaotic movement

- **Graded compression method**

  → visualization of deep areas using HF probe

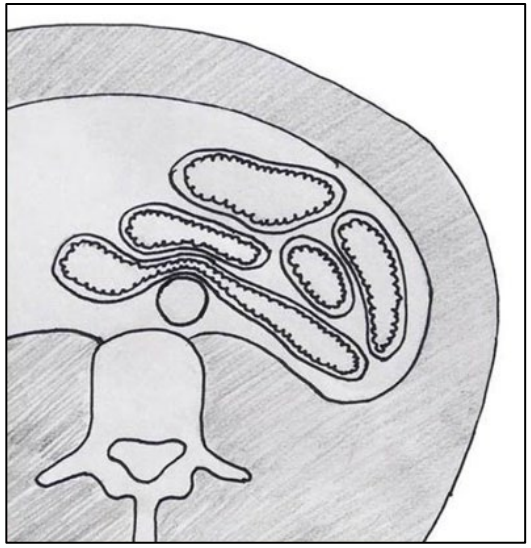

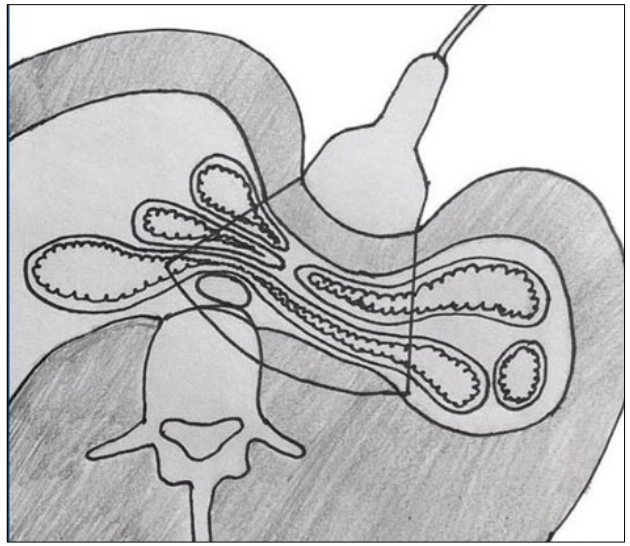

What to look for

- Recognize the different parts of the bowel and surrounding structures

  → **Landmarks!!**

- Normal vs. abnormal bowel wall

Localization of the key anatomy (landmarks)

The most important landmarks: iliac vessels and the psoas muscle

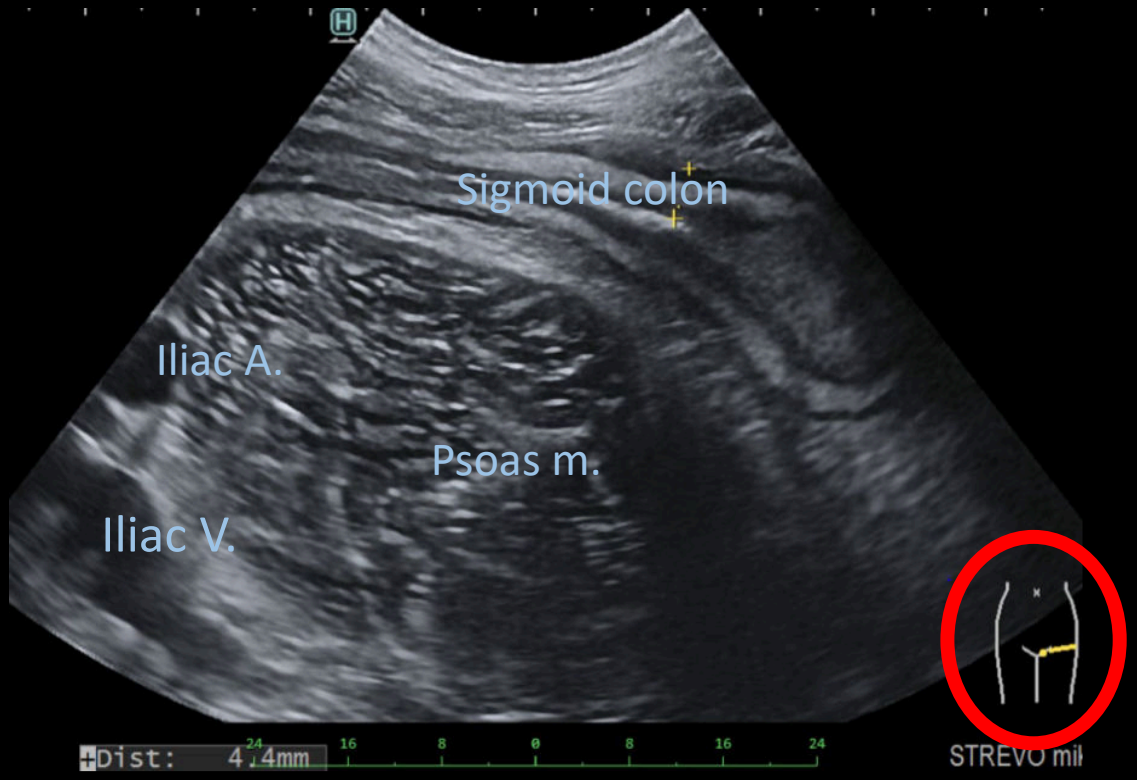

international bowel
ULTRASOUND GROUP

Anatomical landmarks in the mid upper andomen – Finding the Transverse

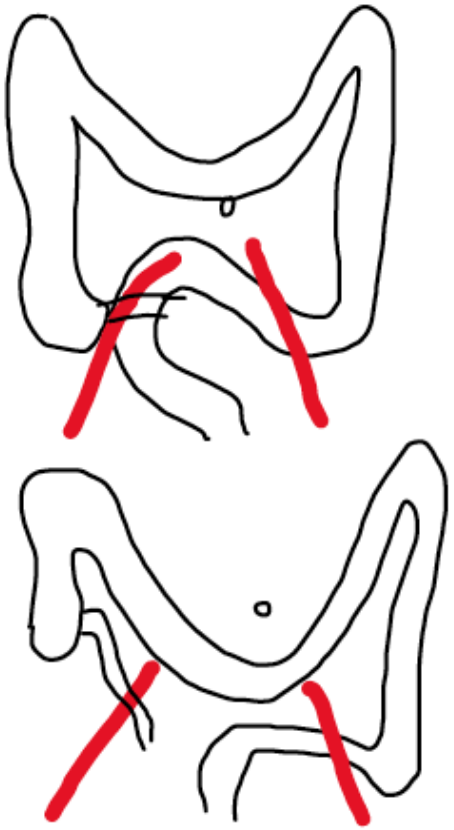

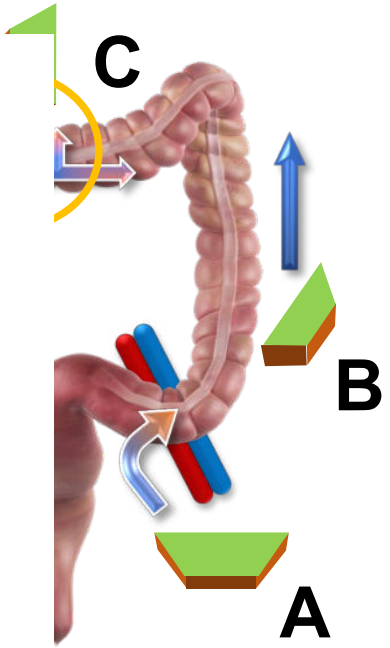

international bowel
ULTRASOUND GROUP

Why are landmarks important?

- to make sure the orientation of the probe is correct
- to optimize the settings of the machine
- to find the correct bowel segment
- to re-orientate if lost
- all of the above

international bowel
ULTRASOUND GROUP

Normal bowel wall

- 5 distinct sonographic layers

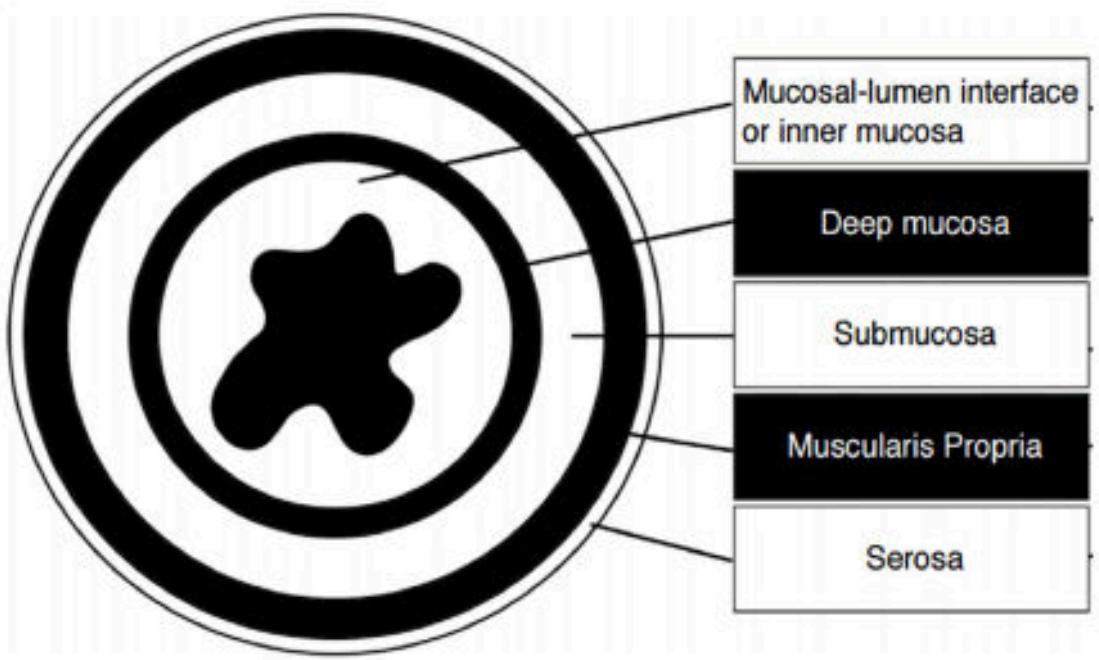

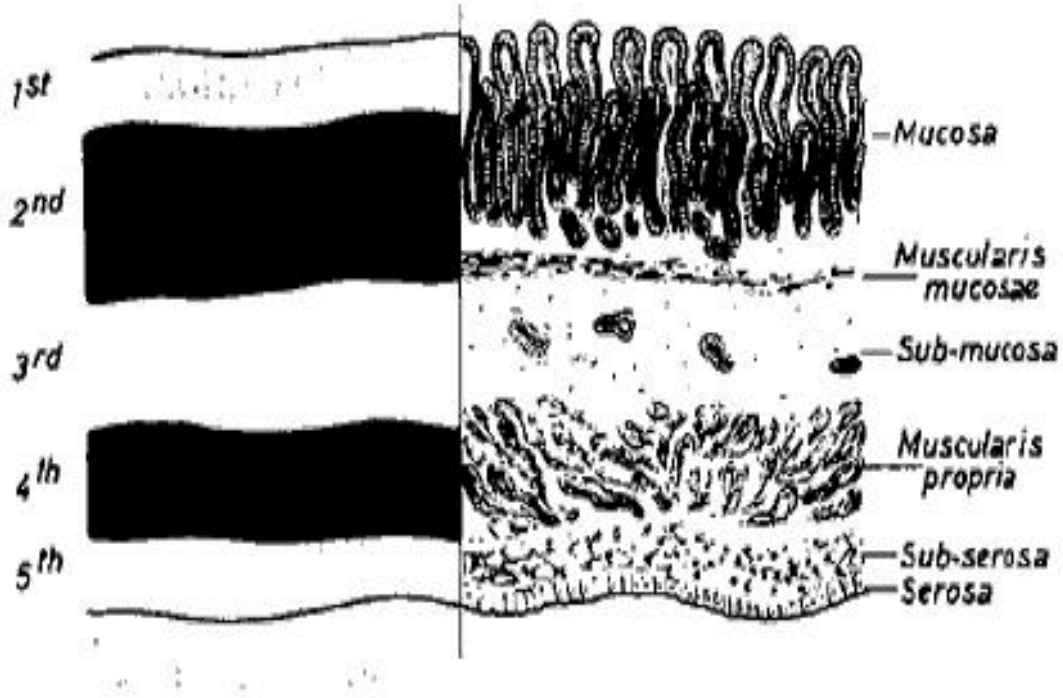

international bowel ULTRASOUND GROUP

Normal bowel wall in ultrasonography

Muscularis (hypoechoic)

Submucosa (hyperechoic)

Mucosa (hypoechoic)

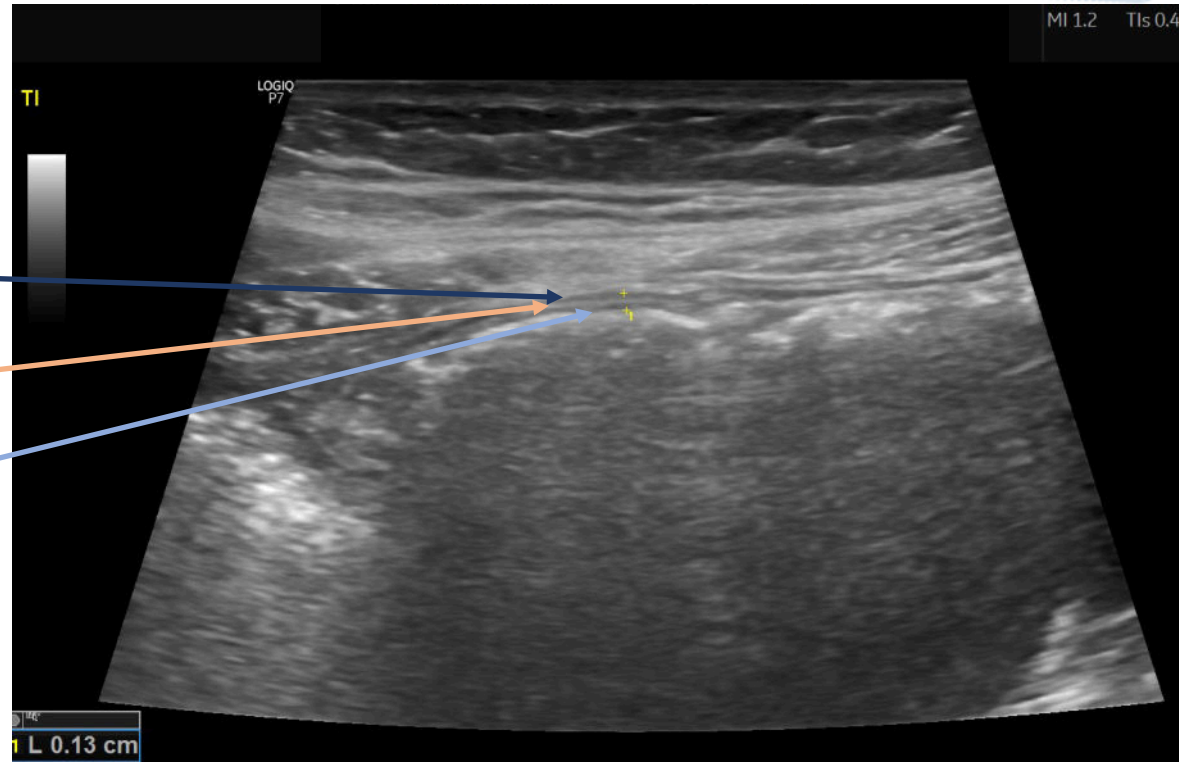

Some practical points:

- Interface echo of serosa mixed in with interface from peritoneum
- Posterior bowel wall often not possible to see due to air in the lumen ➔ Measurements in anterior wall!
- Measure from mucosal hypoechoic layer to muscularis hypoechoic layer
- Avoid measuring at points of haustrations and mucosal folds (overestimation!)
- Keep probe perpendicular to GI wall

Bowel wall thickness (BWT)

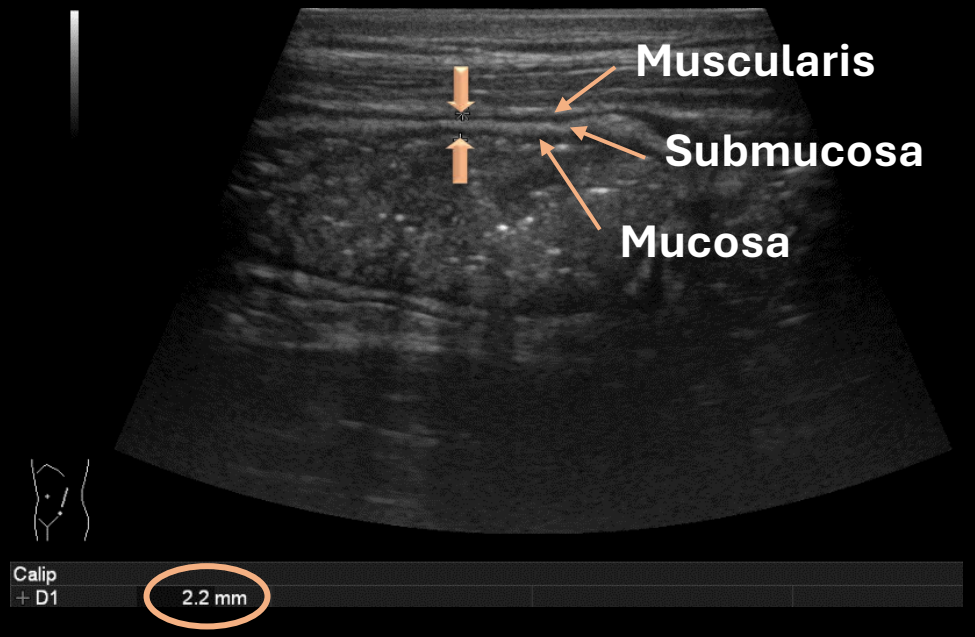

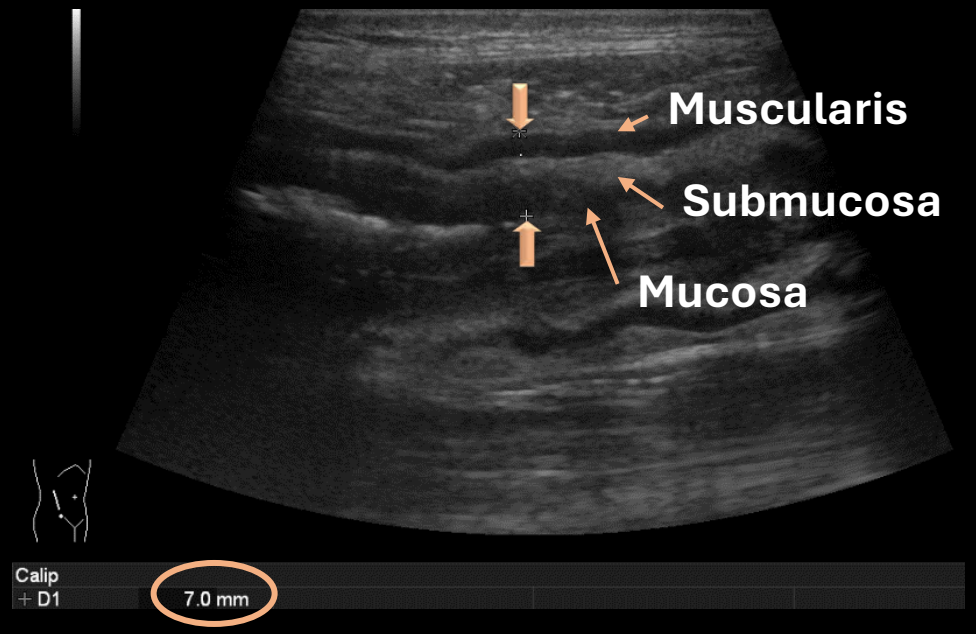

*Measure at right angles to bowel wall layers.

PARAMETERS

- ✓ BWT
- ✓ Stratification
- ✓ Vascularization
- ✓ Margins
- ✓ Haustra
- ✓ Motility
- ✓ Mesentery
- ✓ Lymph nodes
- ✓ Free fluid

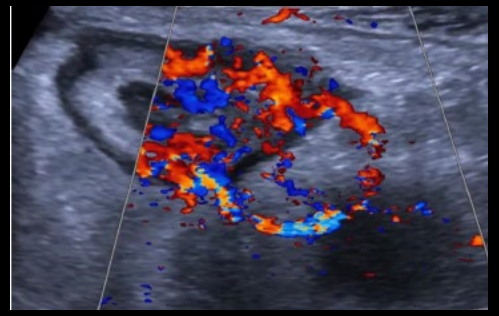

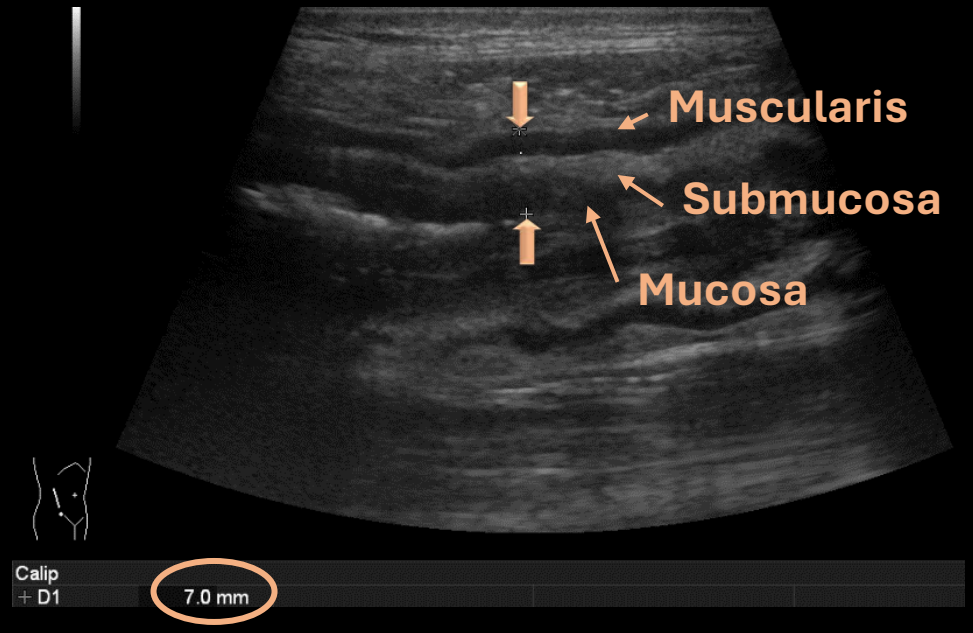

international bowel ULTRASOUND GROUP

KUWAIT GASTROENTEROLOGY ASSOCIATION
رابطة الجهاز الهضمي والكبد الكويتية

Examination technique – Systematic

RECOMMENDATIONS:

10. The scanning of the intestines must involve a systematic approach, LoE 5, GoR C. Strong consensus 12/12

Rectum → Sigmoid → Decending → Transverse → Ascending → Ceacum
→ Terminal Ileum
→ Small bowel

Colon

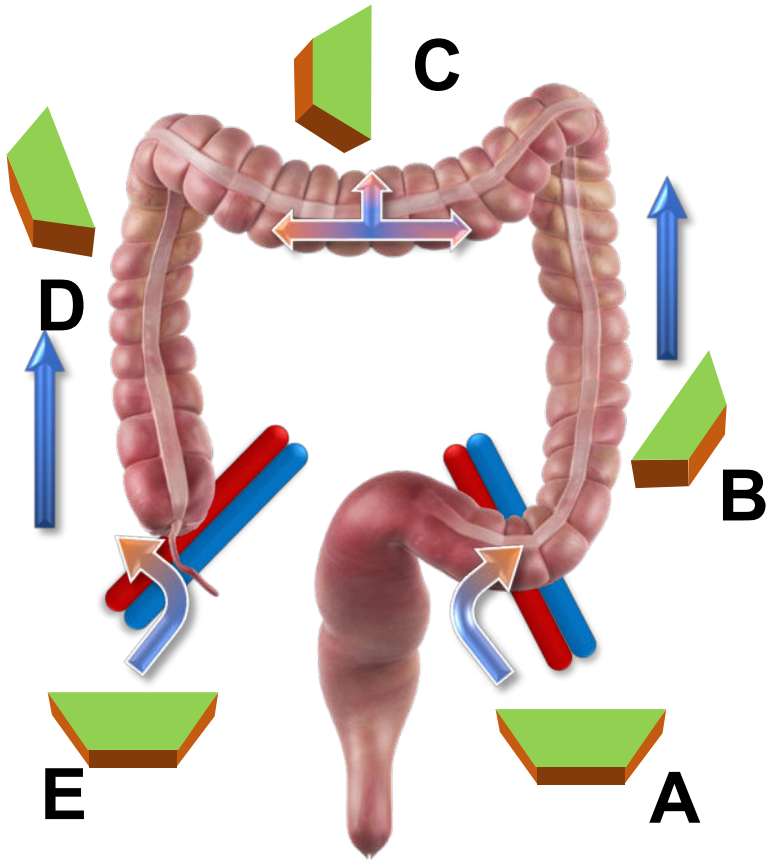

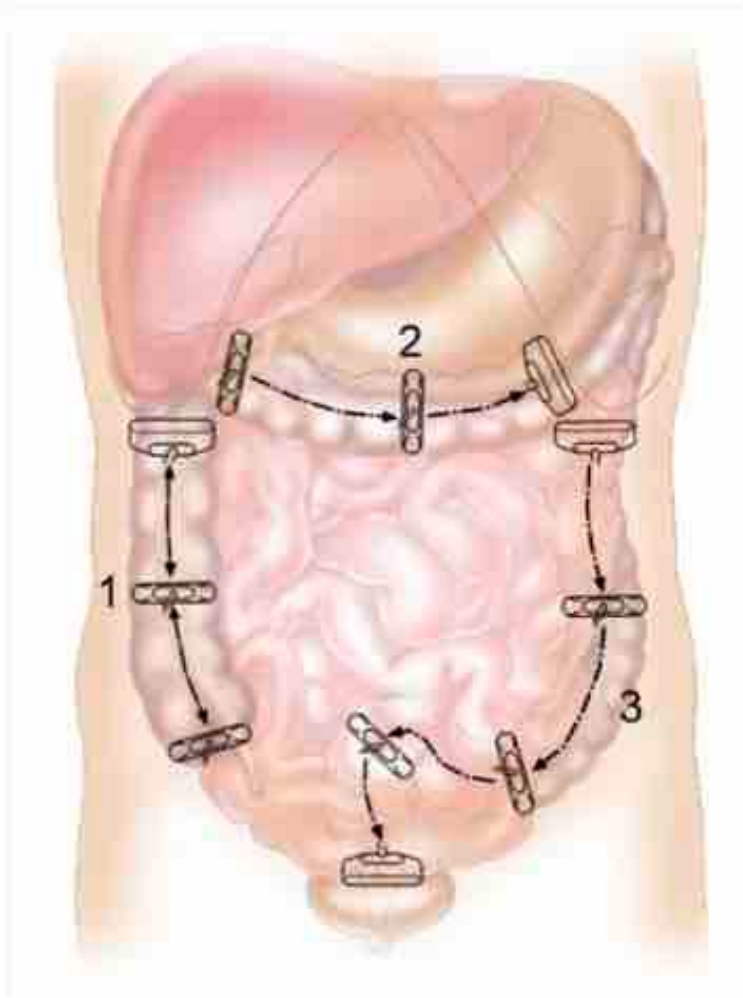

Nylund K et al. EFSUMB Recommendations and Guidelines for Gastrointestinal Ultrasound, Ultraschall Med 2017

international bowel ULTRASOUND GROUP

Rectum

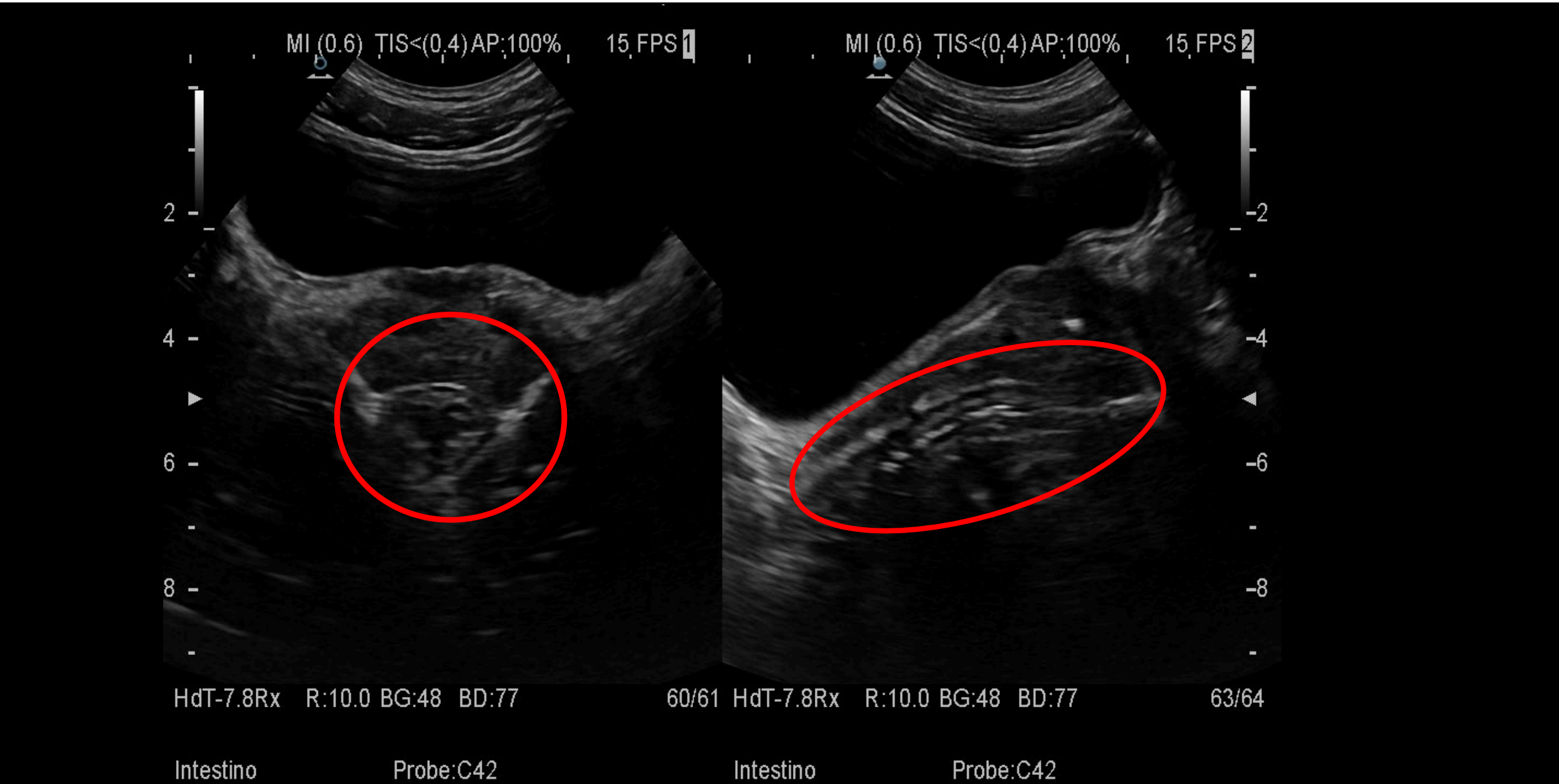

international bowel
ULTRASOUND GROUP

Sigmoid Colon

international bowel
ULTRASOUND GROUP

Sigmoid Colon

international bowel
ULTRASOUND GROUP

Descending colon

international bowel
ULTRASOUND GROUP

Transverse colon

international bowel
ULTRASOUND GROUP

Ascending colon

Terminal ileum

international bowel
ULTRASOUND GROUP

Examination technique
Systematic approach

- Small bowel

"mowing the lawn" technique

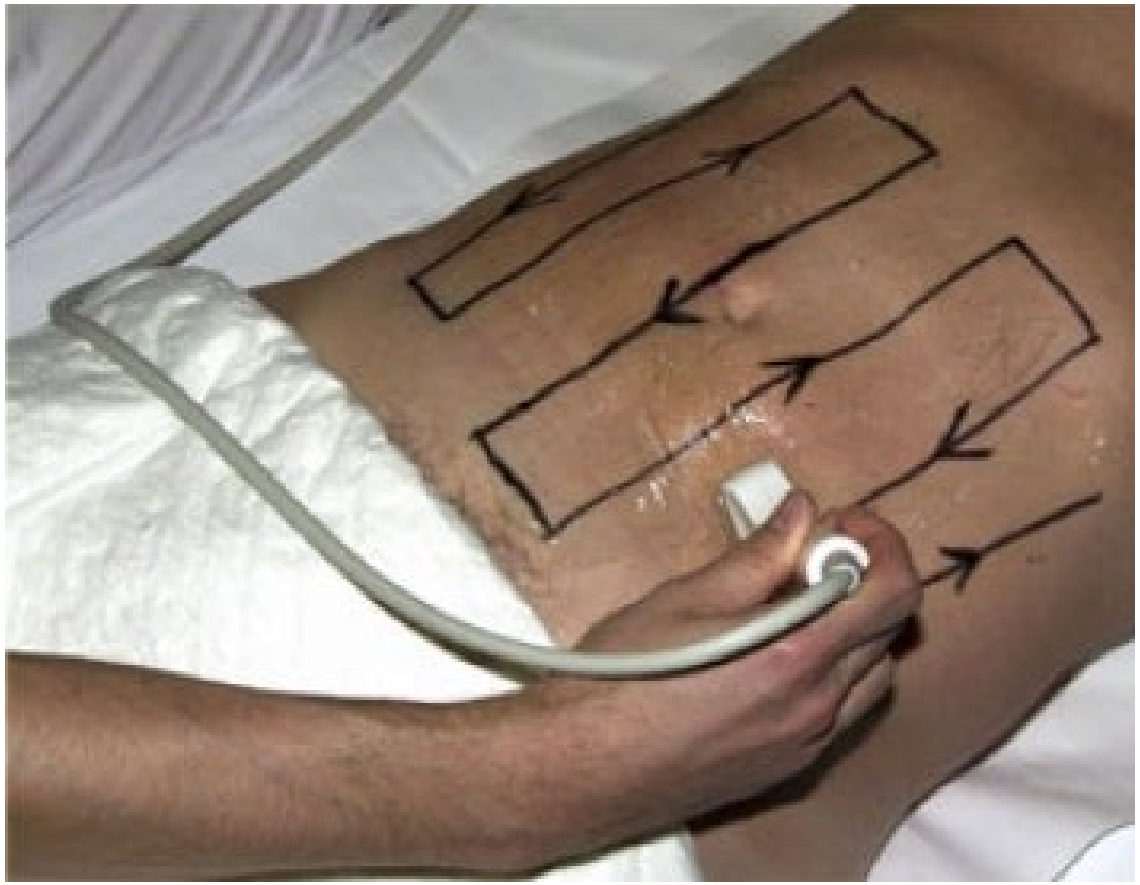

international bowel
ULTRASOUND GROUP

Differentiation between small and large bowel on IUS

Take home messages

- ✓ Preparation: none
- ✓ Probe 5-8 MHz
- ✓ orientation
- ✓ know what to look for
- ✓ anatomical landmarks
- ✓ ultrasound scan plans
- ✓ systematic approach

international bowel
ULTRASOUND GROUP

Thank you