

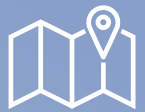Not all you see is IBD

Mariangela Allocca

MD, PhD

Head of IBD Center

IRCCS Hospital San Raffaele, Milan, Italy



Kuwait City, Kuwait, November 21st – 22nd, 2025

Intended Learning Outcomes

By the end of this session, the learner will be able to:

1. List common conditions (e.g., infectious colitis, diverticulitis, ischemic colitis, appendicitis, IBS-related changes, neoplasia) that can mimic IBD on intestinal ultrasound (IUS).
2. Explain the characteristic IUS features that may help differentiate IBD from other intestinal pathologies, including differences in bowel wall thickness, vascularity, wall stratification, and distribution patterns.
3. Critically evaluate IUS findings in the context of the patient's full clinical presentation, integrating history, lab values, and other imaging results, to establish the most likely diagnosis and avoid misinterpretation.

Disclosure

Dr. Mariangela Allocca received consulting fees from Nikkiso Europe, Mundipharma, Alfasigma, Janssen, Abbvie, Ferring, Galapagos, Sandoz, Lilly and Pfizer

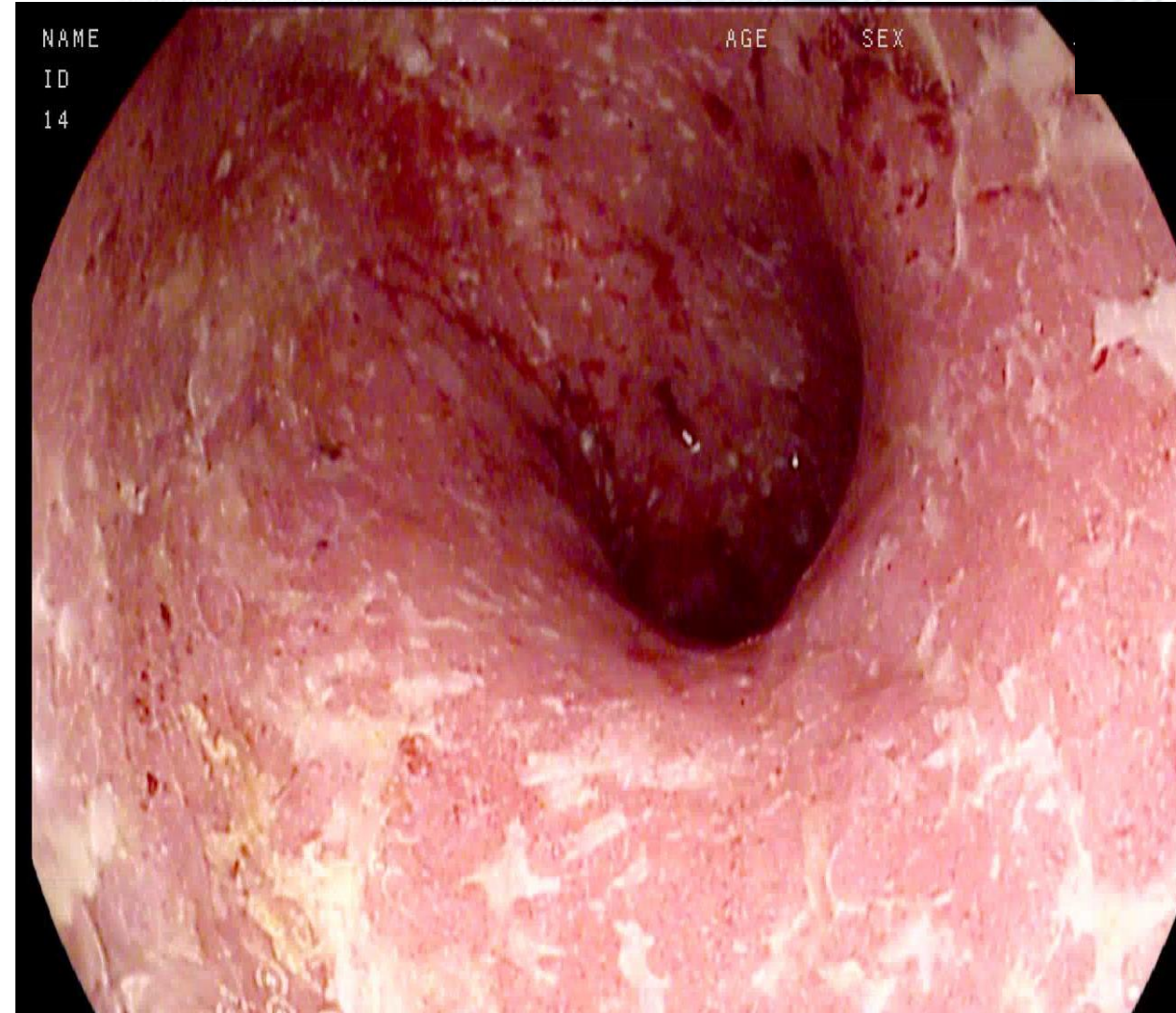
Valeria, 35 years old

- Family history of Crohn's disease and kidney cancer
- Smoking: no; Alcohol: no
- Polycystic ovary syndrome

- **07/2019** Abdominal pain and bloody diarrhea
- Stool coltures negative
- Colonoscopy: ulcerations from the transverse colon to the rectum
- Histology confirmed ulcerative colitis
- Topical and oral mesalamine

05/2020

- Hospitalization for acute severe colitis
- Initial improvement with intravenous prednisone, then worsening
- Sigmoidoscopy: diffuse ulcerations, friable mucosa. Histology: CMV colitis
- Ganciclovir 5 mg/kg e.v. bid for 2 weeks



06/2020

- 3-4 stools/day with traces of blood, mucus. Urgency
- Calprotectin 545 mcg/g
- Start IFX + AZA

06/2020

- 3-4 stools/day with traces of blood, mucus. Urgency
- Calprotectin 545 mcg/g
- Start IFX + AZA

- **Week 14**, She is fine. Calprotectin 87 mcg/g
- Visit scheduled for week 22

06/2020

- 3-4 stools/day with traces of blood, mucus. Urgency
- Calprotectin 545 mcg/g
- Start IFX + AZA

- Week 14, She is fine. Calprotectin 87 mcg/g
- Visit scheduled for week 22

However.....

2 weeks later

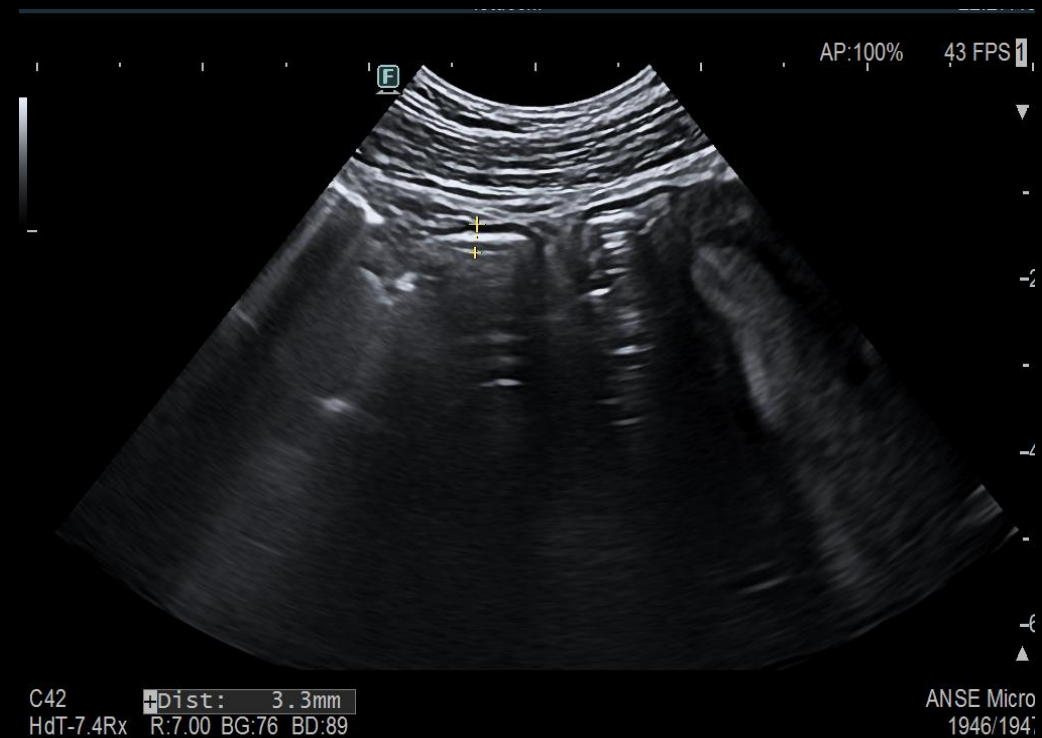
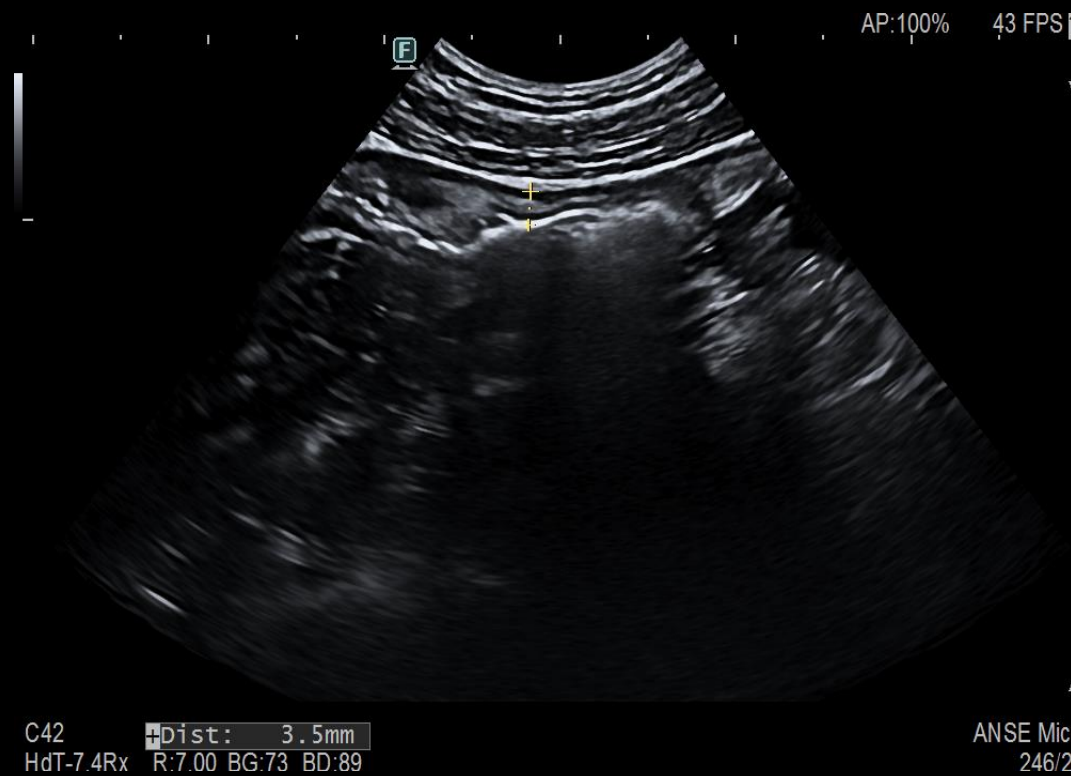
- Phones help line because of
 - Abdominal pain in the right lower quadrant
 - Fever
 - Diarrhea, 4-5 liquid stools without blood

2 weeks later

- Phones help line because of
 - Abdominal pain in the right lower quadrant
 - Fever
 - Diarrhea, 4-5 liquid stools without blood
 - WBC 9000/mm³, Hb 13.7, CRP 5.5 mg/L
 - calprotectin 78
 - Stool cultures: negative

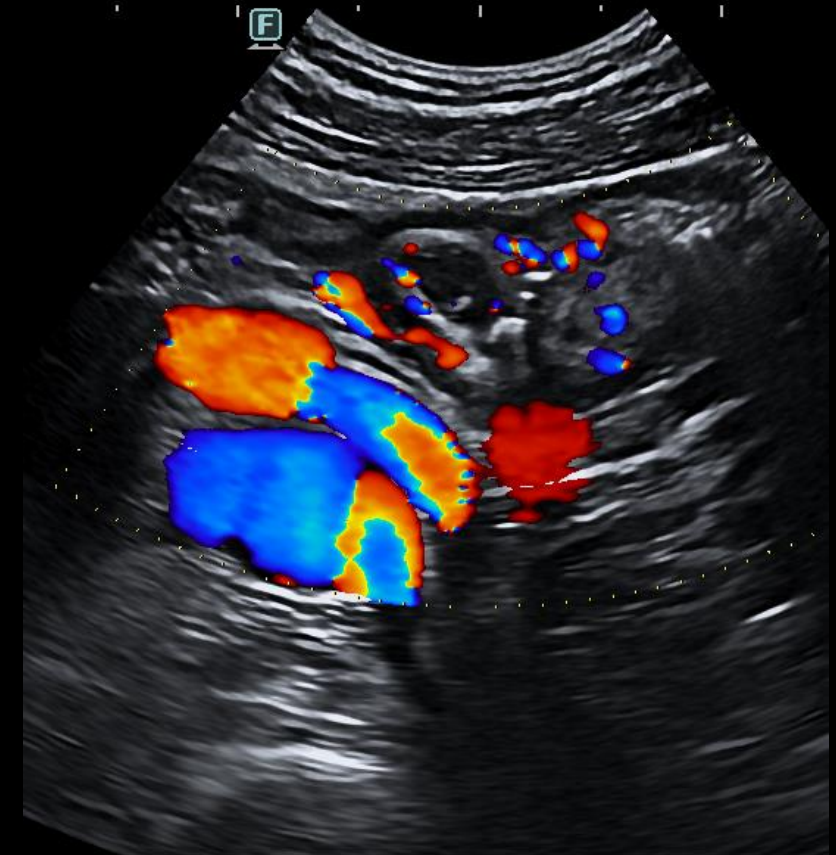
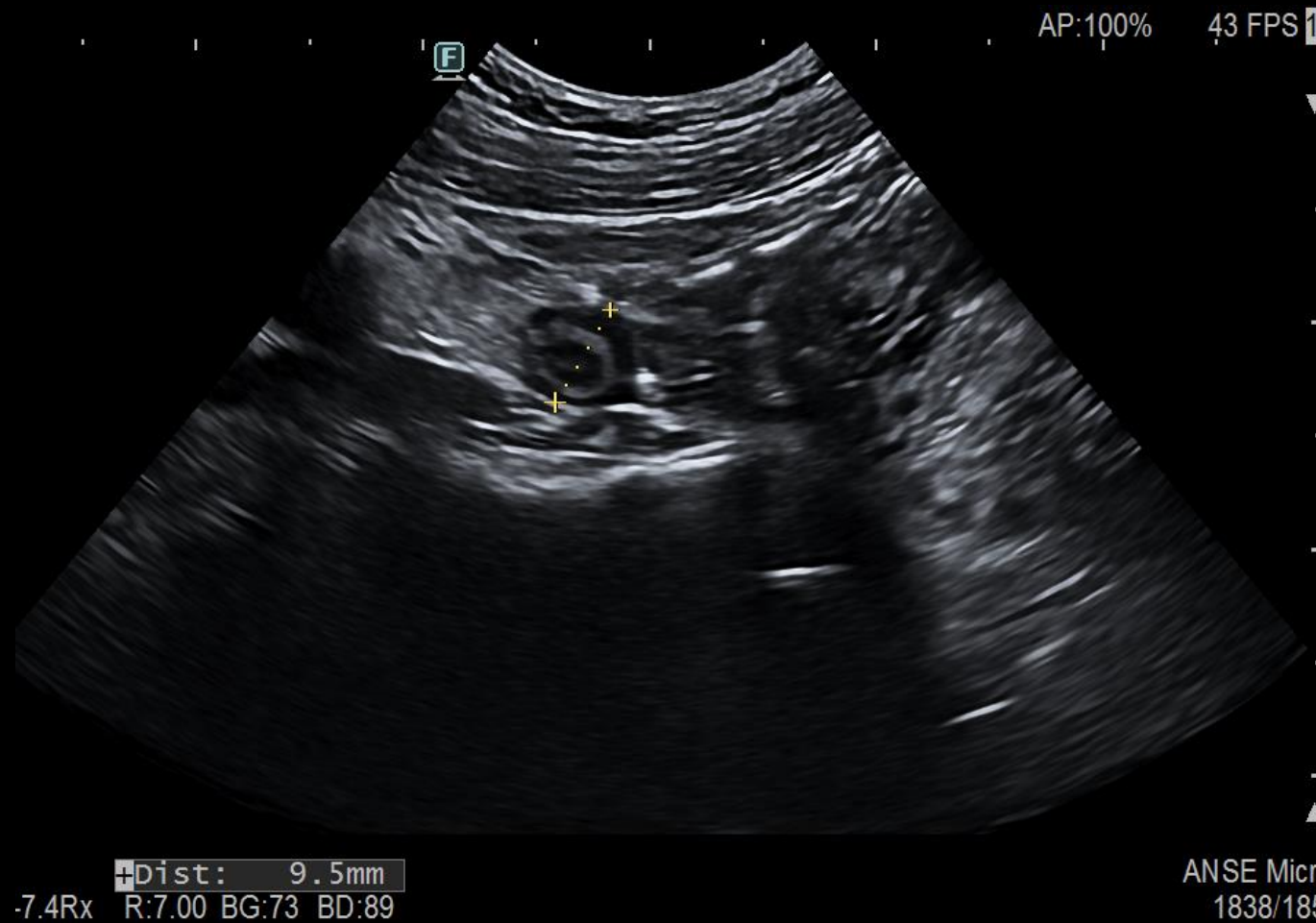

Intestinal ultrasound: terminal ileum and colon





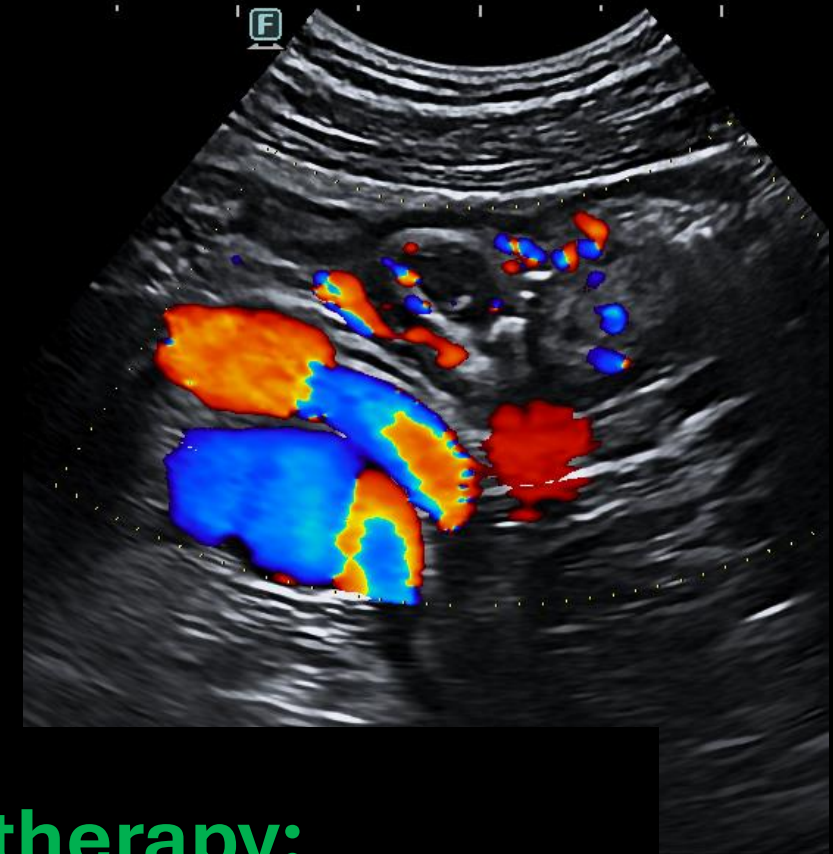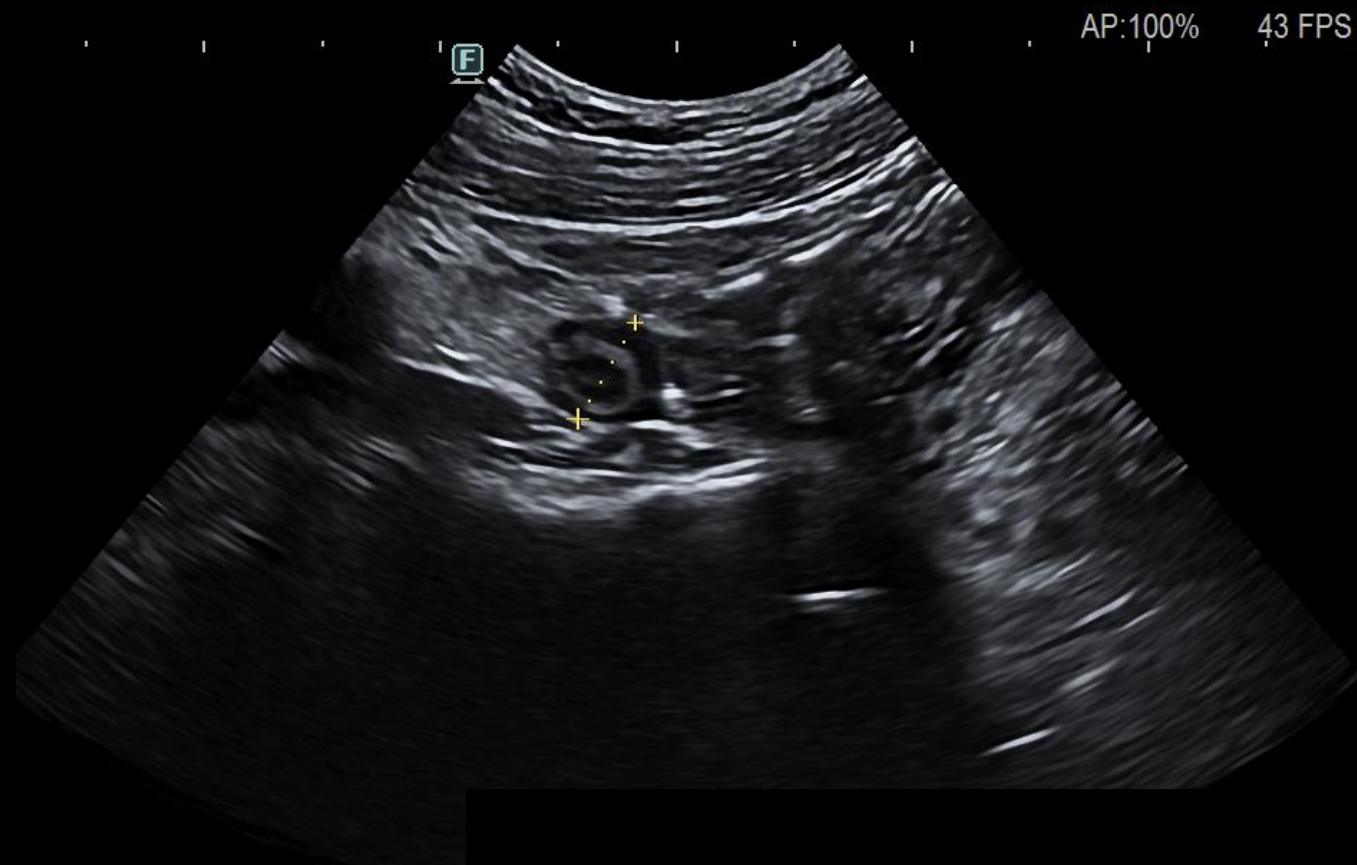
Intestinal ultrasound:



What's your guess?



Intestinal ultrasound:



Dist: 9.5mm

-7.4Rx R:7.00 BG:73 BD:89

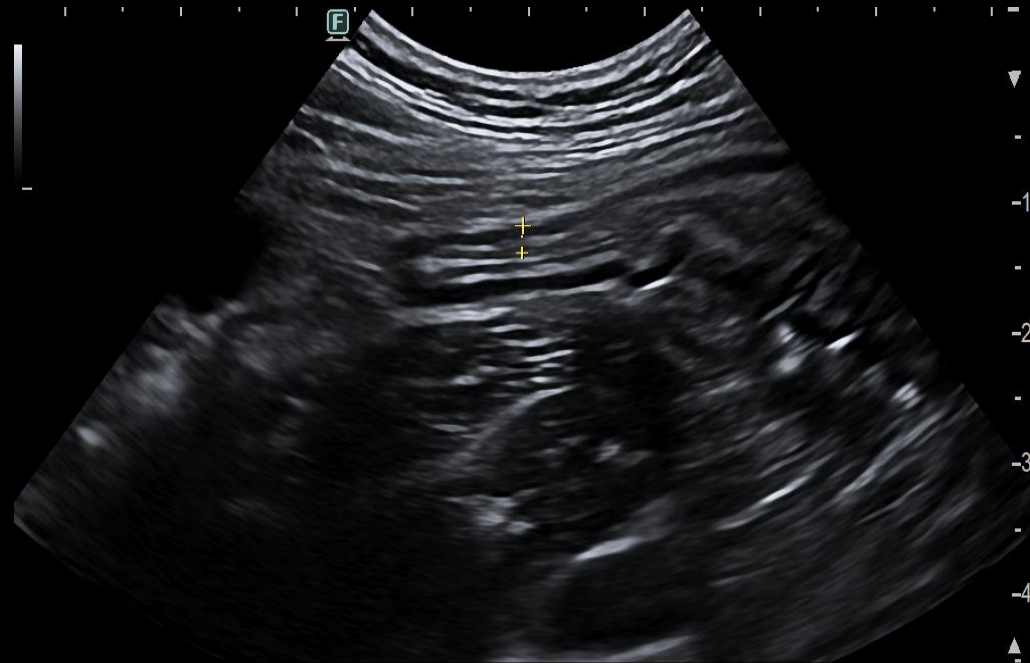
**Double antibiotic therapy:
ciprofloxacin + metronidazol for 10 days**

2 weeks later

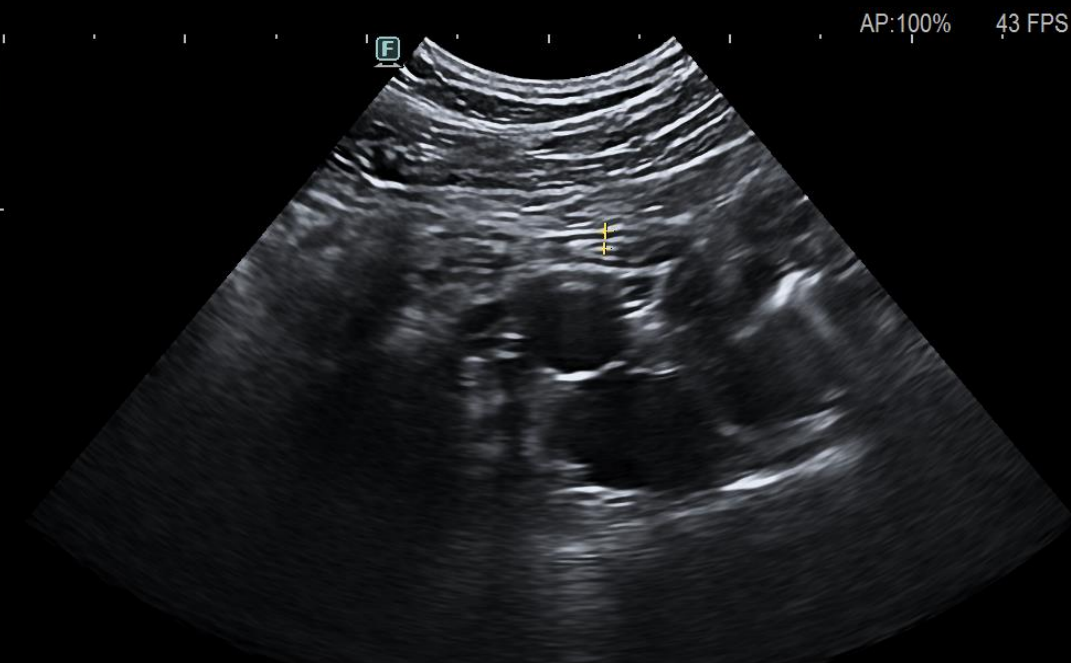
- Resolution of diarrhea, no fever, no abdominal pain



Intestinal ultrasound



C42 Dist: 2.1mm
HdT-7.4Rx R:5.00 BG:73 BD:89



ANSE Micro. C42 Dist: 1.9mm
343/348 HdT-7.4Rx R:7.00 BG:76 BD:89

ANSE Mic
1119/1'

Valeria, 35 years old

- Colonoscopy at week 24: Mayo 0
- Stop AZA at week 24, continues IFX
- She is fine

Elena Sophie, 20 years old

- Off campus student
- Daughter of doctor
- Family history of ulcerative colitis

- Diarrhea for 10 days, 8-9 stools/day
- No blood, presence of mucus
- Urgency
- Mild abdominal pain
- Weight loss of 2 kg

Elena Sophie, 20 years old

Diarrhea of recent onset

- What to do?
- Which investigations?

Investigations

- Full blood count –
- C-reactive protein –
- Stool cultures and *Clostridium difficile* toxin –
- Fecal calprotectin –

Investigations

- Full blood count –
- C-reactive protein –
- Stool cultures and *Clostridium difficile* toxin –
- Fecal calprotectin –



ONGOING

Investigations

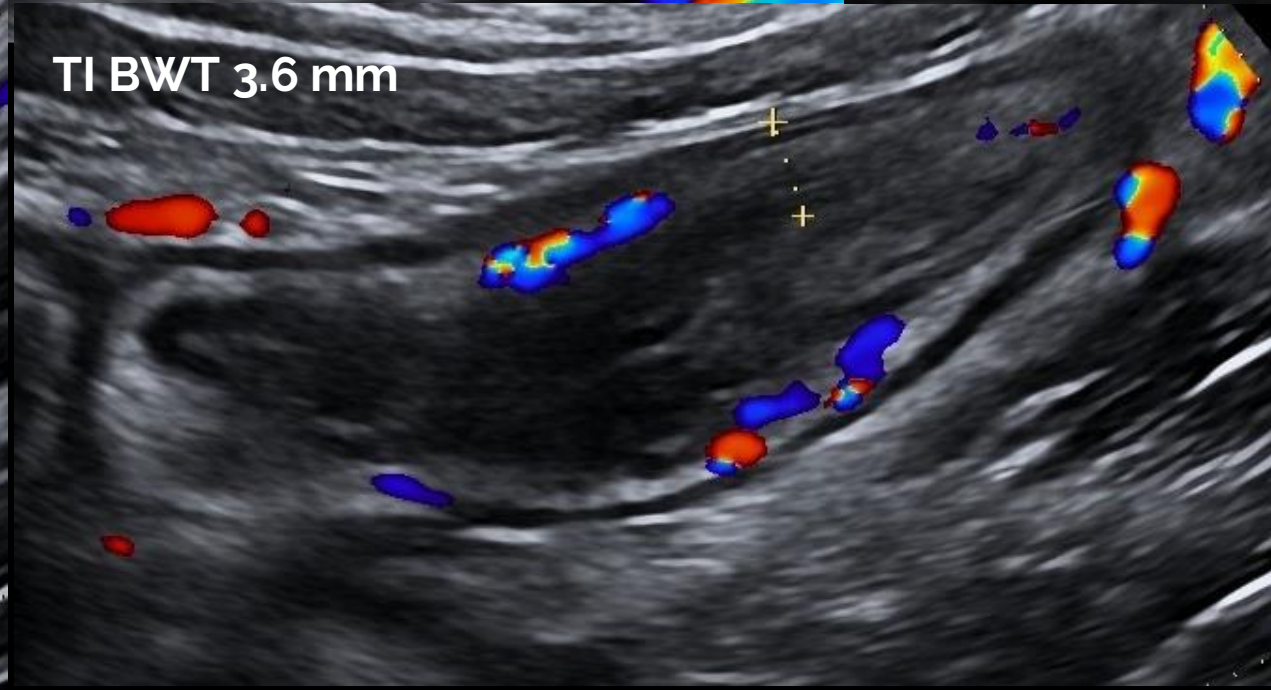
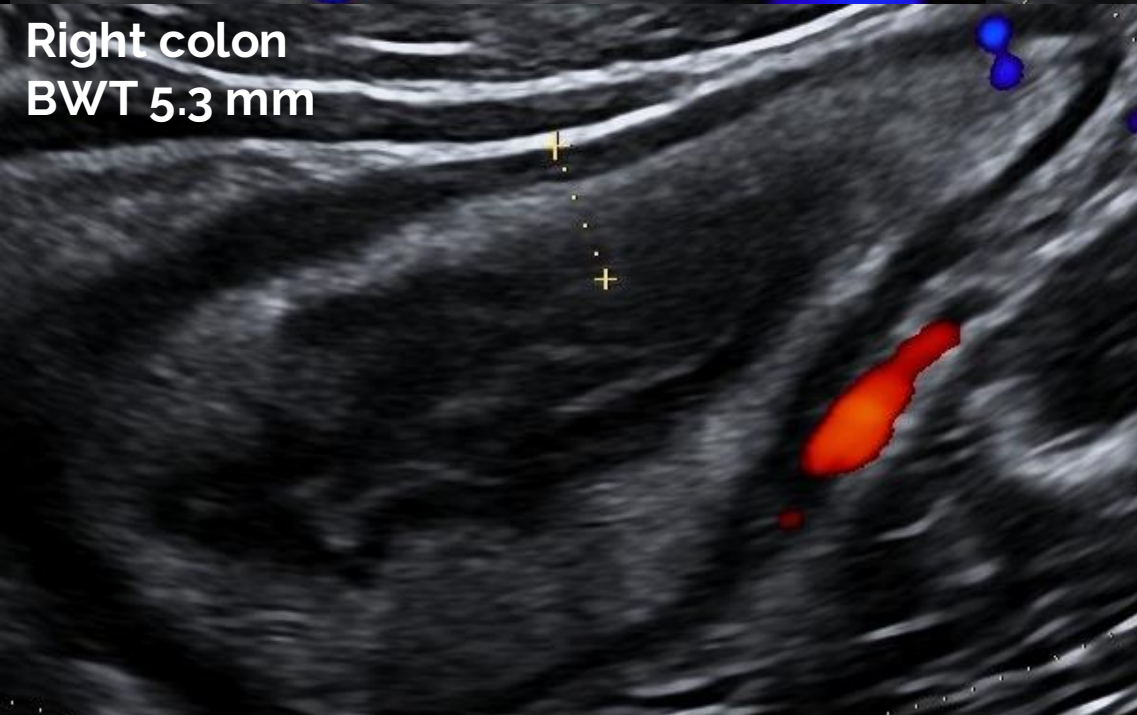
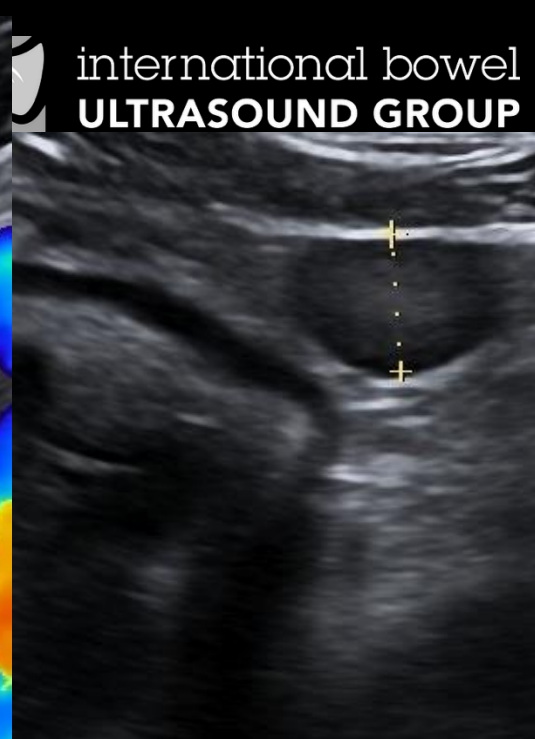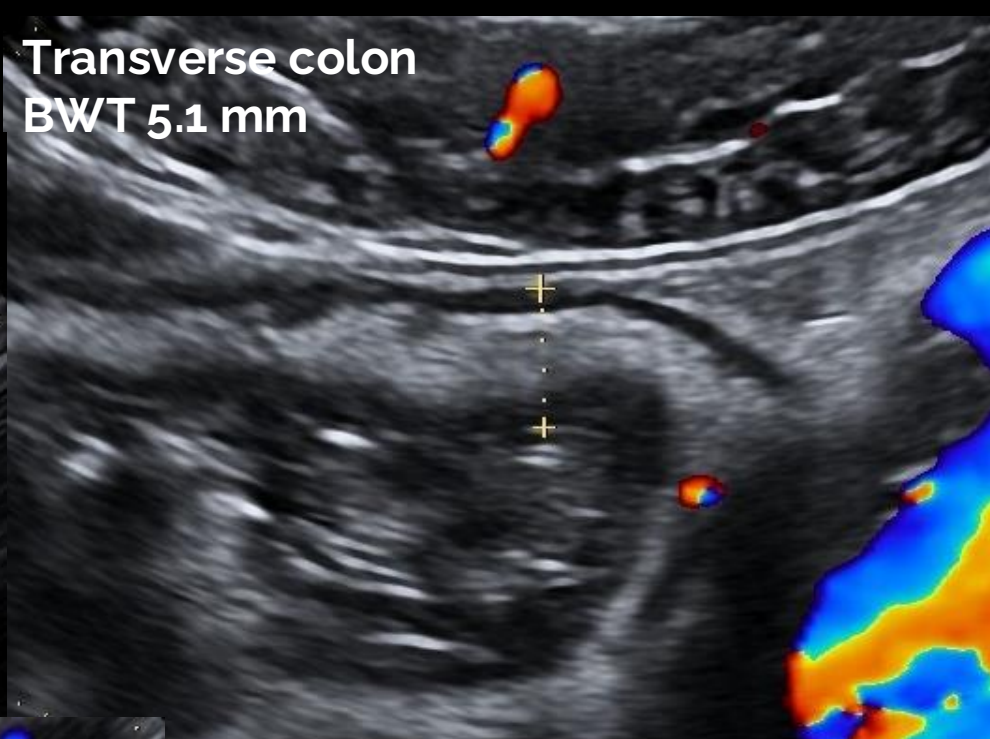
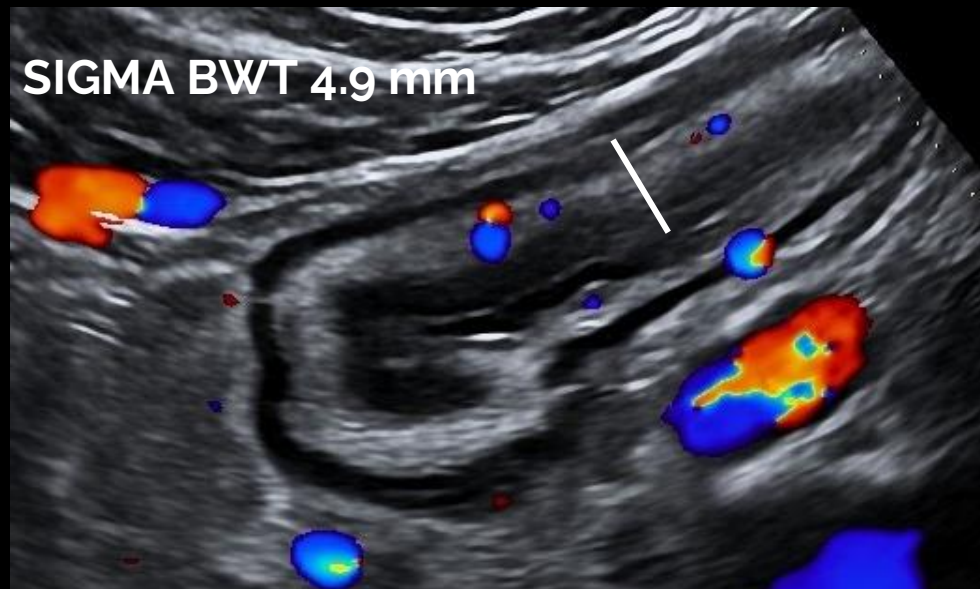
- Full blood count –
- C-reactive protein –
- Stool cultures and *Clostridium difficile* toxin –
- Fecal calprotectin –

- Intestinal ultrasound:



ONGOING

Intestinal ultrasound





Elena Sophie, 20 years old

- Which is your guess?

Investigations

- Full blood count – WBC 12000, Neutrophil 7500, Hb 15
- C-reactive protein – 110 mg/L
- Fecal calprotectin – 1160 mcg/g
- *Clostridium difficile* toxin – negative
- Stool cultures – *Campylobacter jejuni*

Treatment

- Azitromycin 500 mg for 3 days

Treatment

- Azitromycin 500 mg for 3 days

Investigations one month later:

Fecal calprotectin 10 mcg/g, CRP 0.7 mg/L

No thickening

Giuseppina, 72 years old

- Smoker, 10 cigarettes a day
- Hypercholesterolemia on statin therapy
- Abdominal pain for 6 months
- Positive occult blood

- Colonoscopy: stop at 28 cm due to inability to continue.
Multiple diverticula with hyperemic and edematous mucosa
- CT colonography: sigma with multiple diverticula

Treatment

- Mesalamine 800 mg 3 capsules and cycles of rifaximin

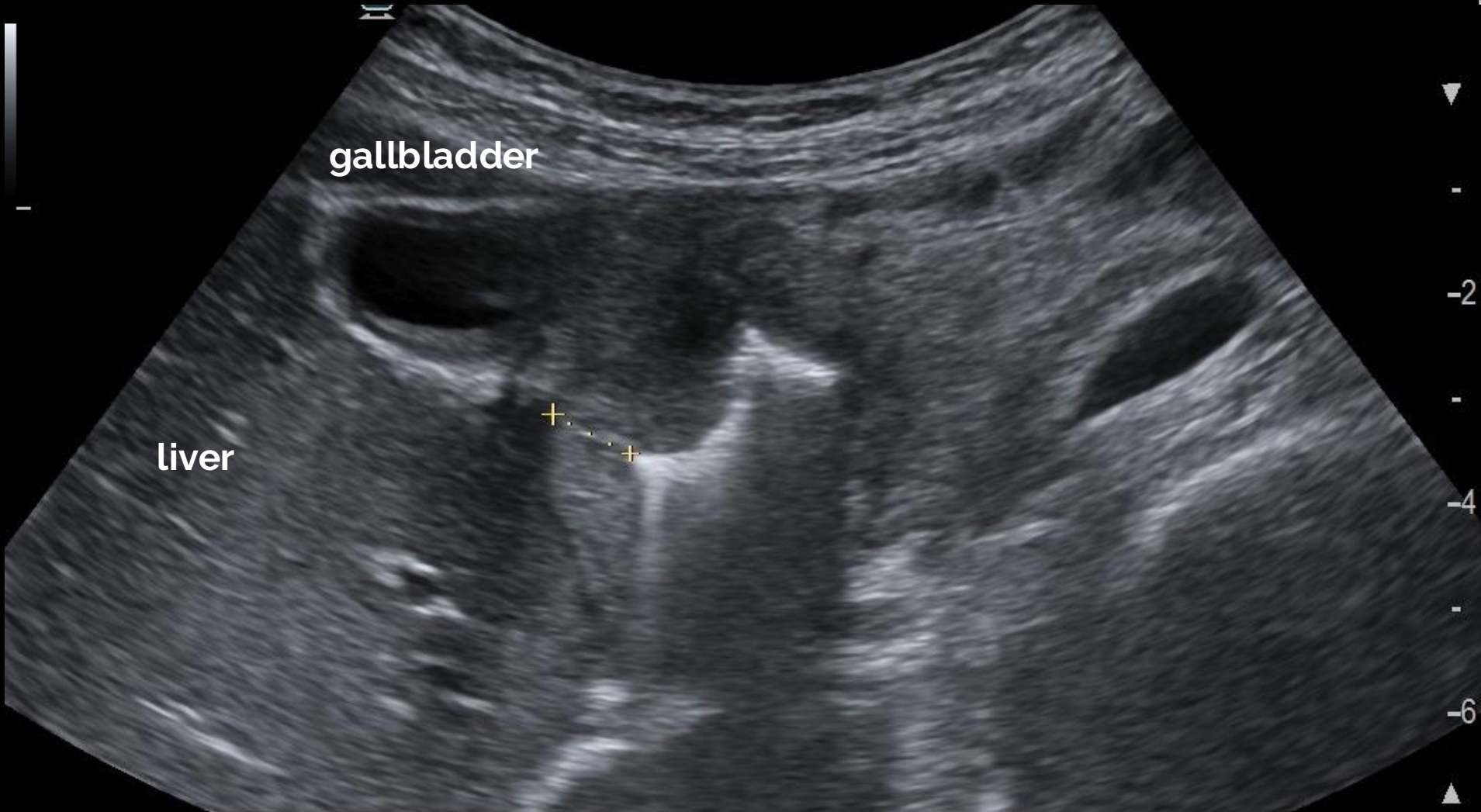
Treatment

- Mesalazin 800 mg 3 capsules and cycles of rifaximin
- Persistent abdominal pain and dyspepsia one month later
- 1-2 stools/day without blood or mucus
- Blood investigations: Hb 11.5 g/dL, MCV 80, ferritin 30 mcg/L, CRP 5.8 mg/L, LFTs N
- Fecal calprotectin: 58 mcg/g

Intestinal ultrasound



international bowel
ULTRASOUND GROUP



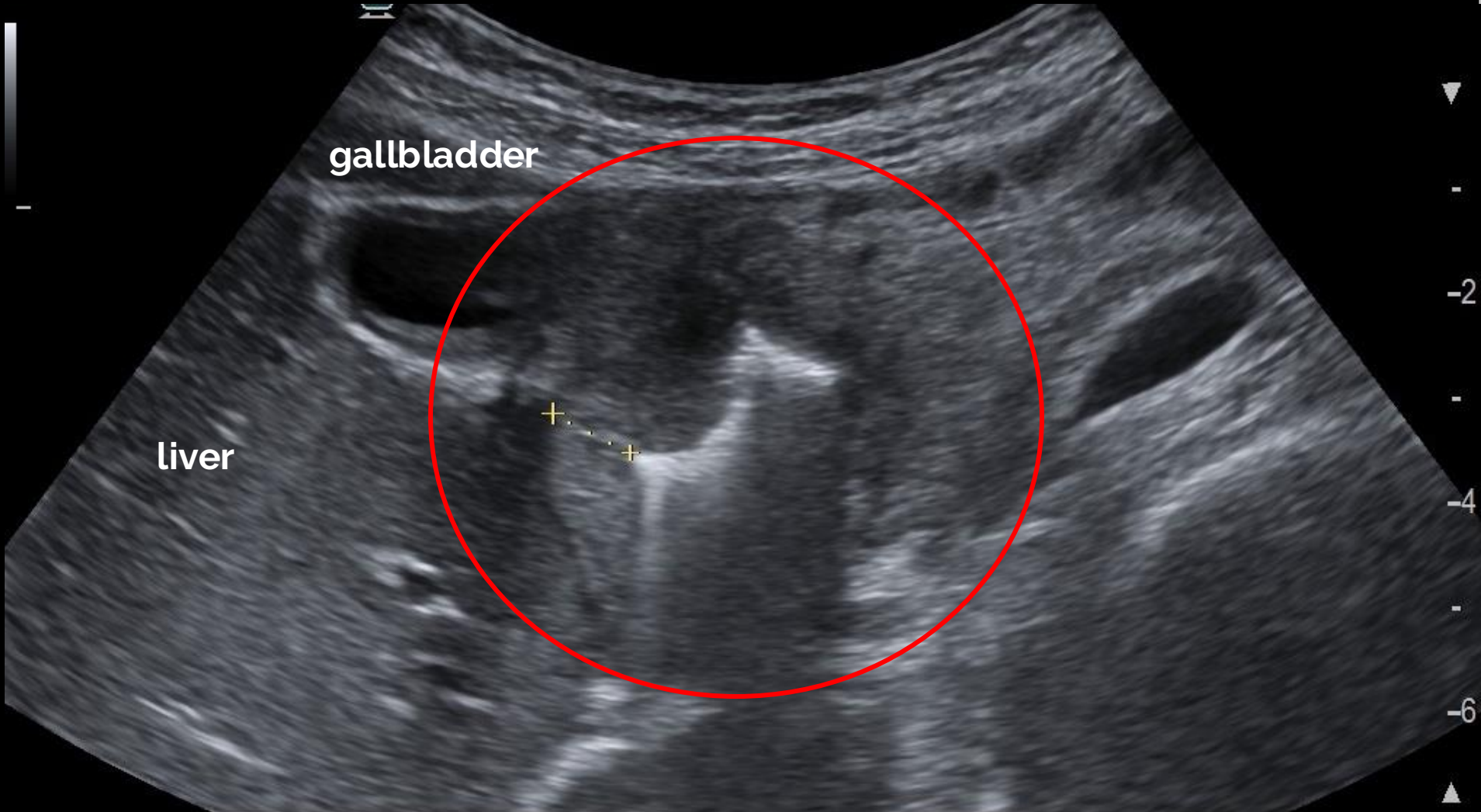
C252 **+**Dist: 8.3mm
HdT-5.9Rx R:8.00 BG:70 BD:84

ADDOME 1.
928/929

Intestinal ultrasound



international bowel
ULTRASOUND GROUP



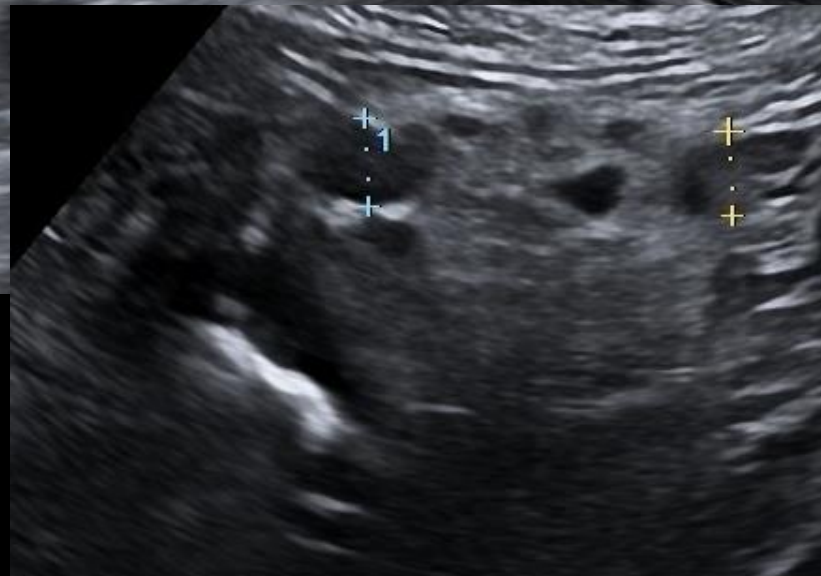
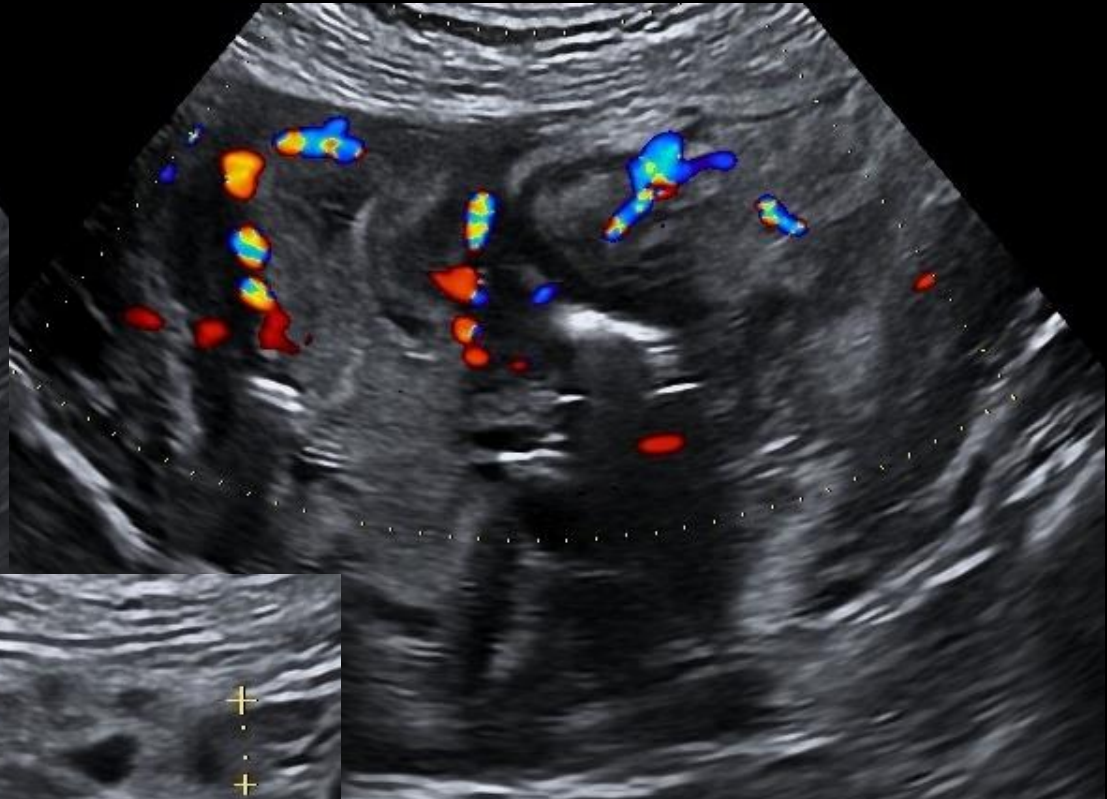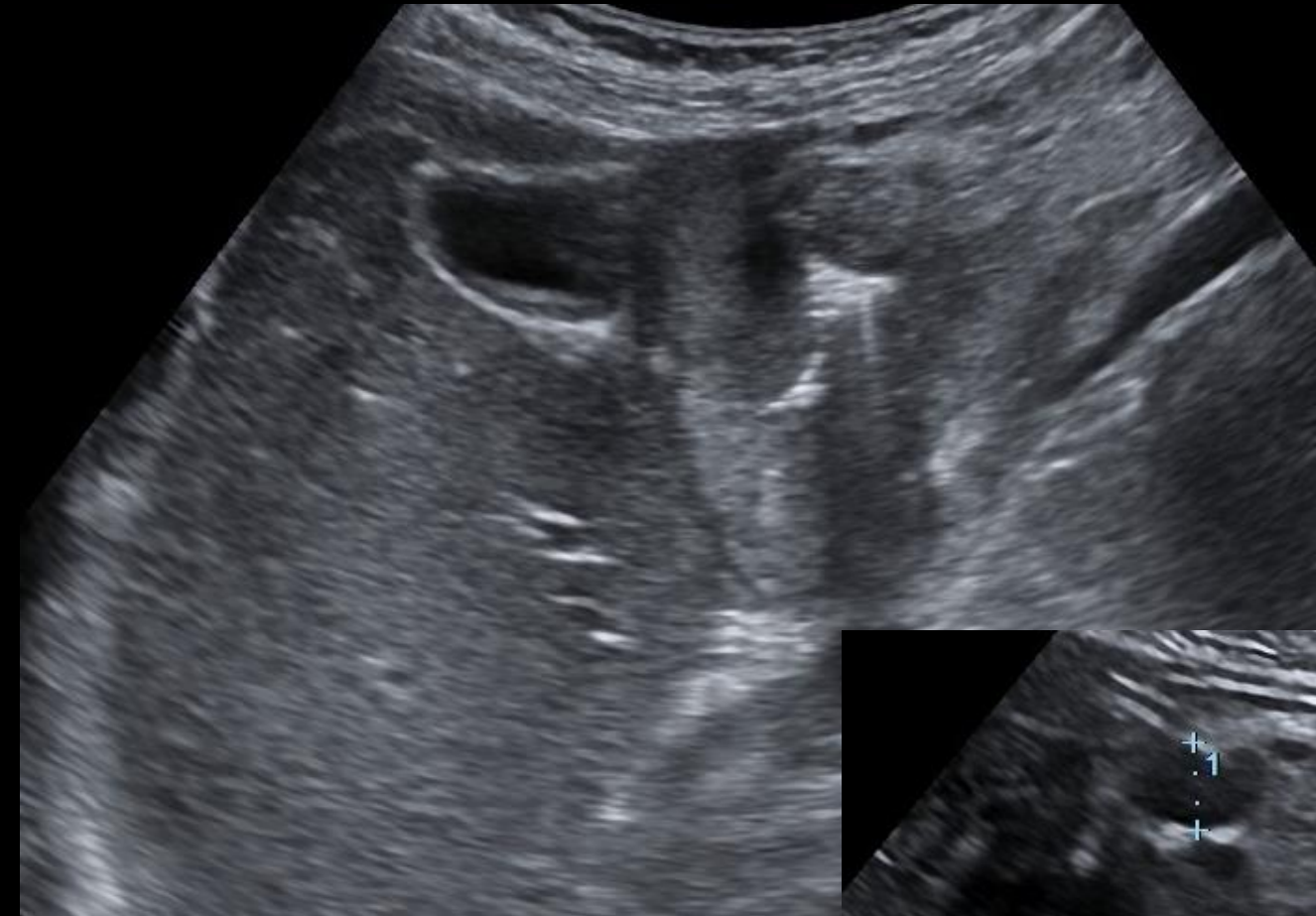C252 **+**Dist: 8.3mm
HdT-5.9Rx R:8.00 BG:70 BD:84

ADDOME 1.
928/929

Intestinal ultrasound



international bowel
ULTRASOUND GROUP



Intestinal ultrasound



international bowel
ULTRASOUND GROUP

TI BWT 1.2 mm



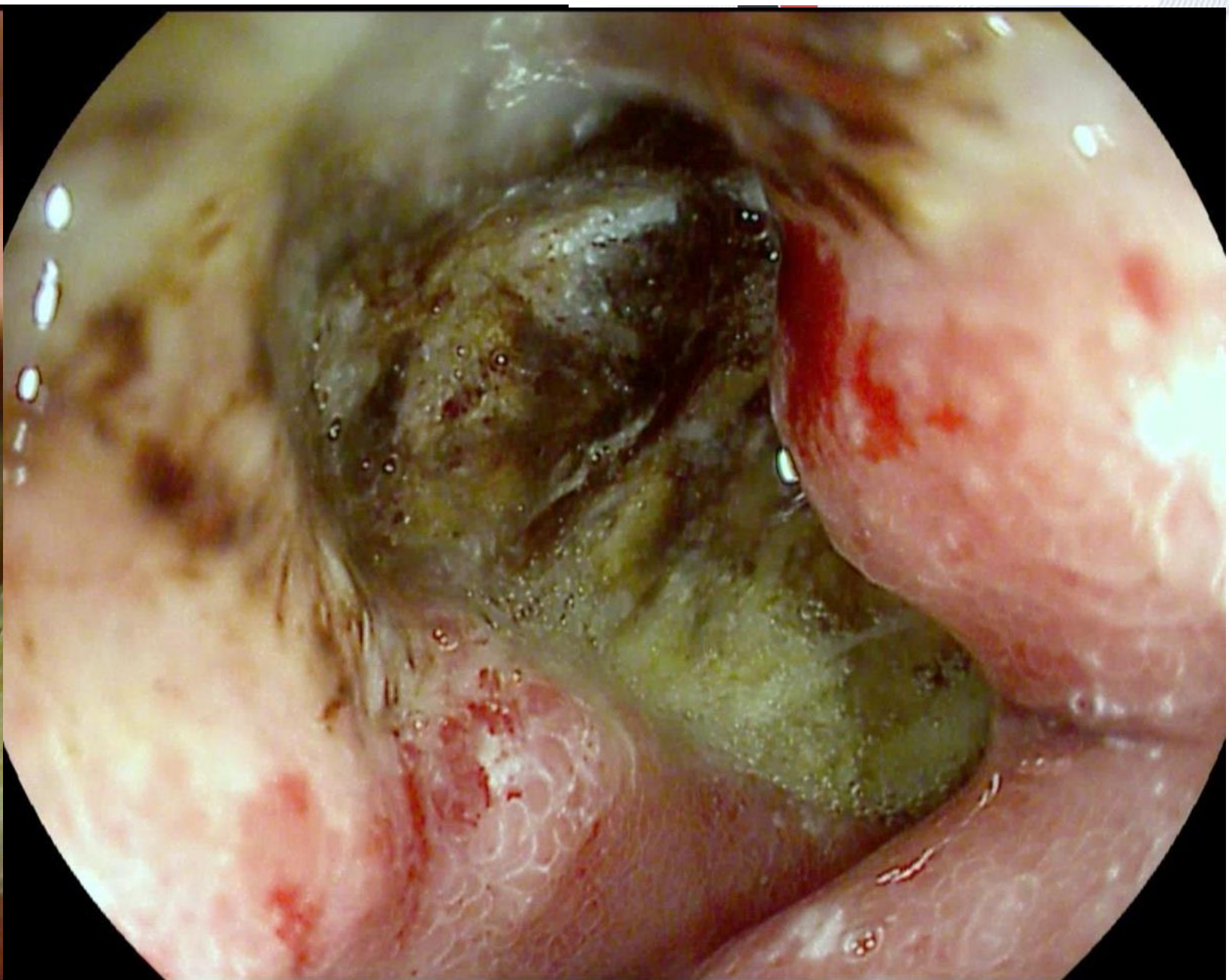
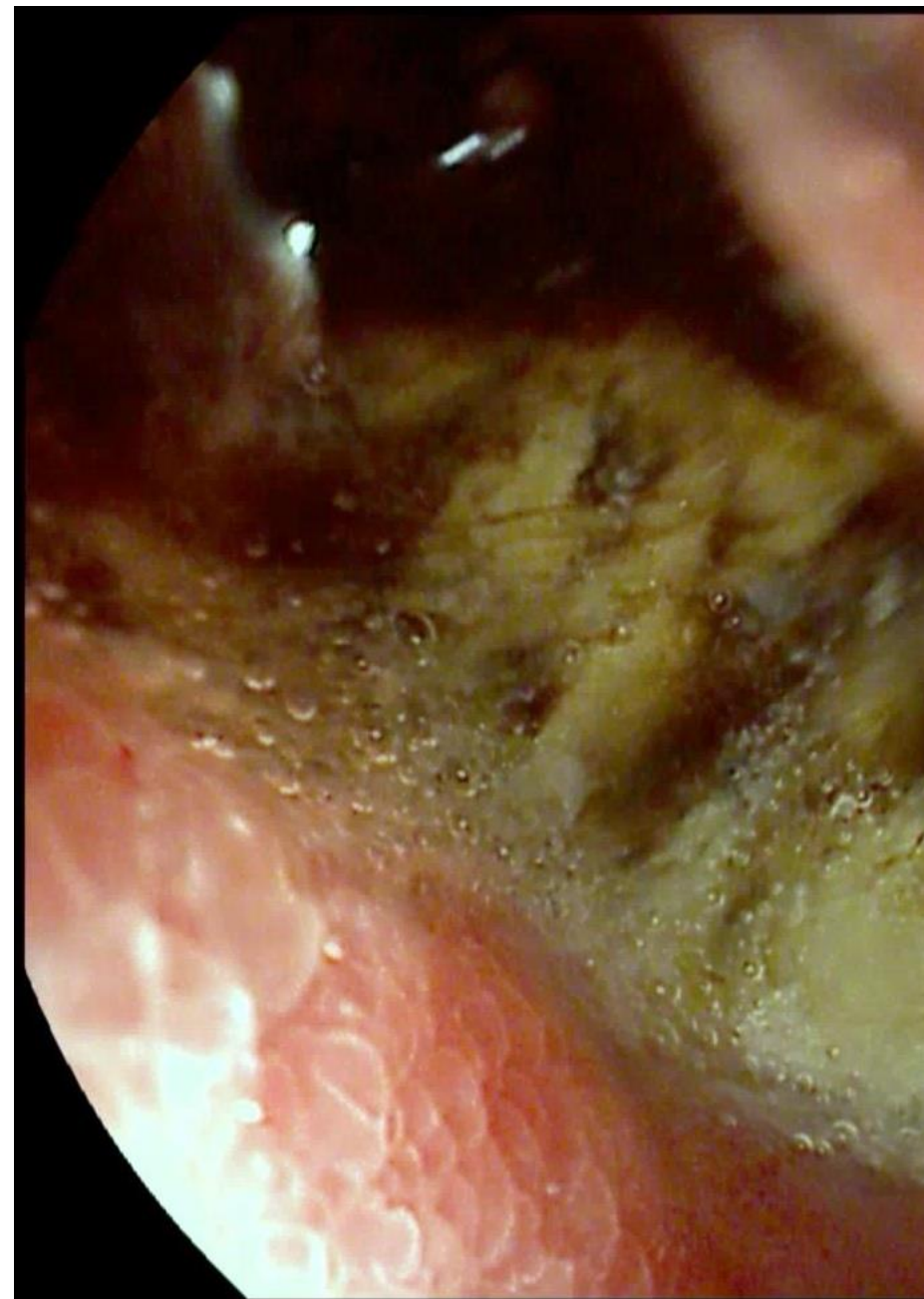
Sigma BWT 1.4 mm



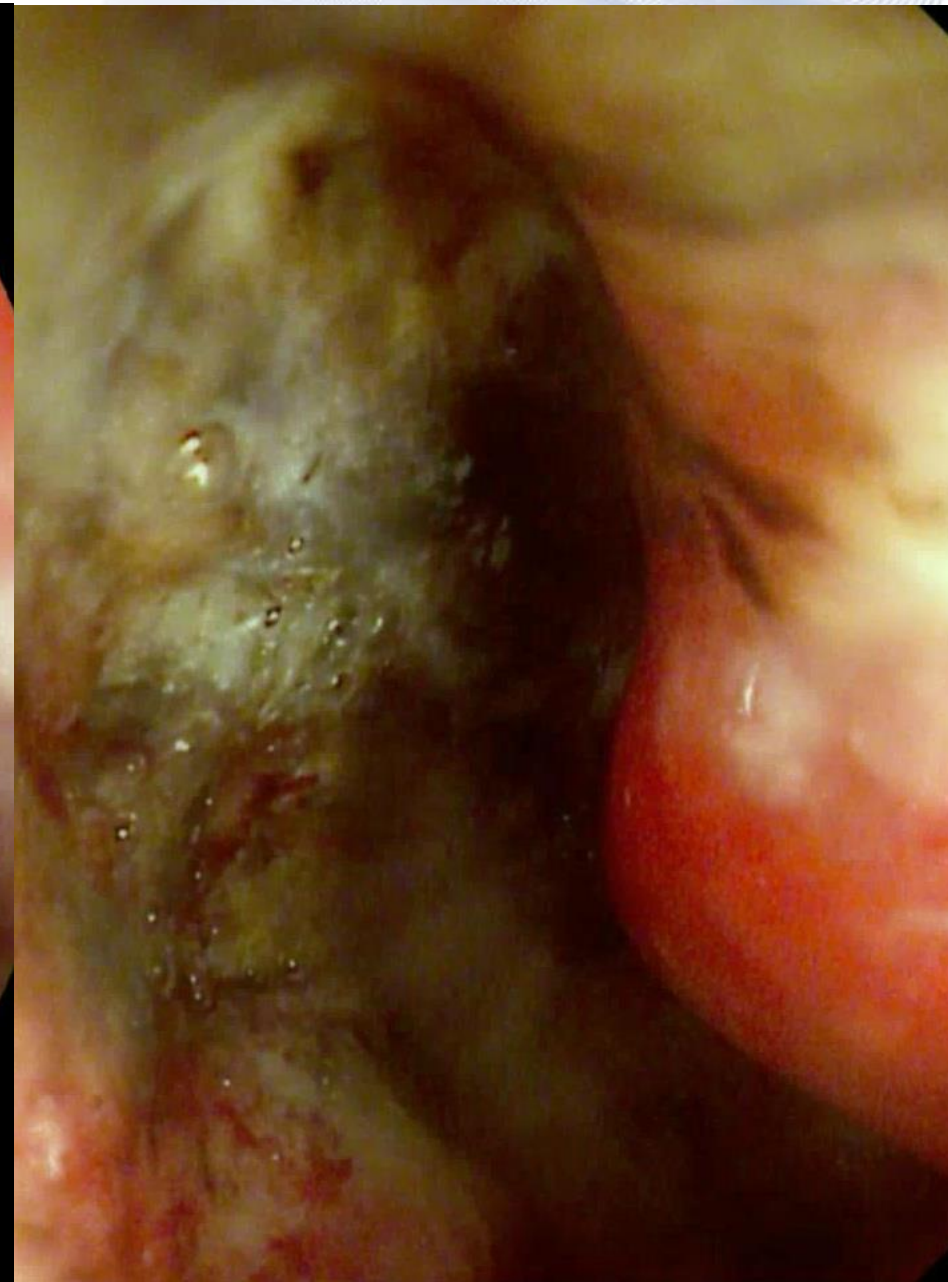
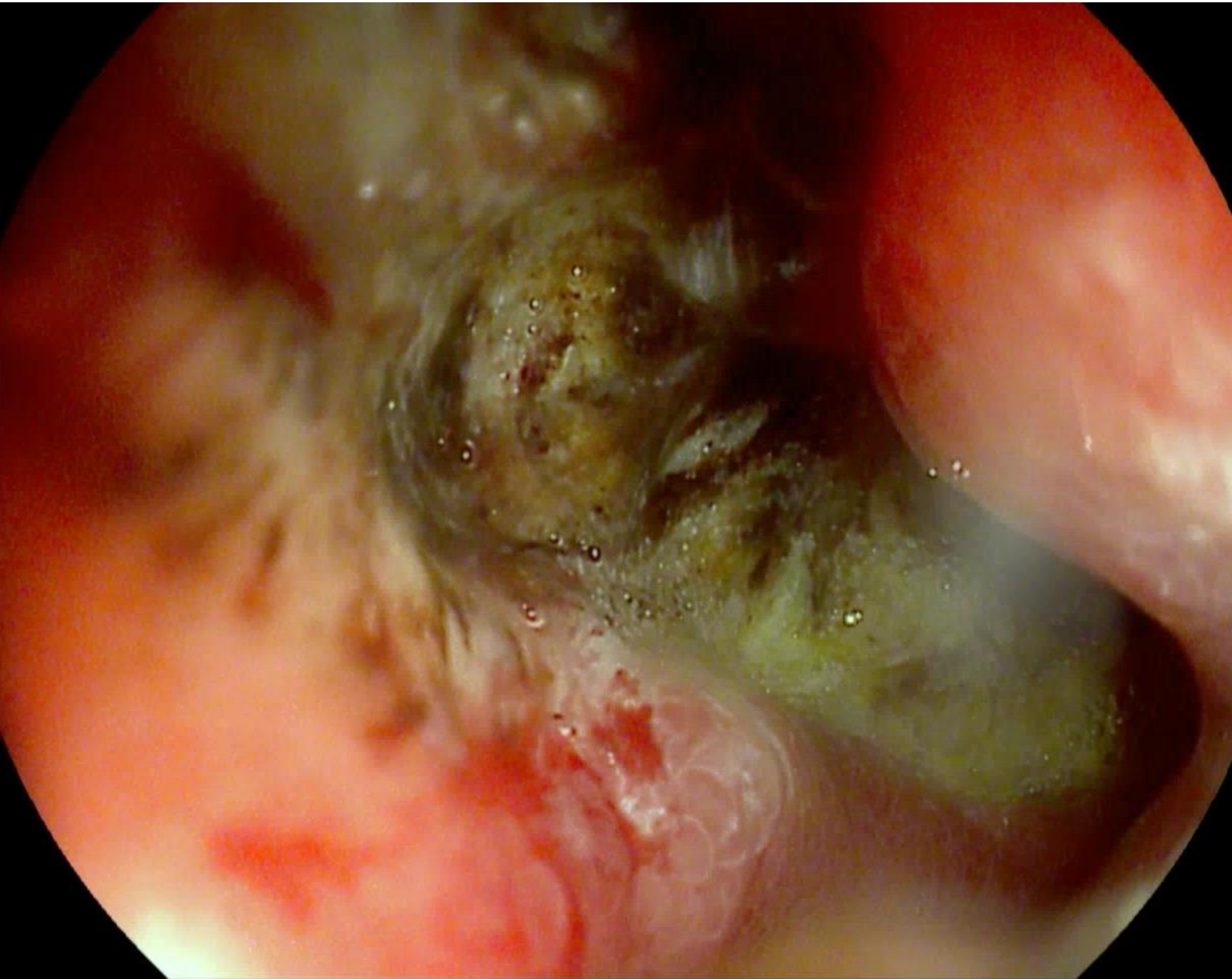
Giuseppina, 72 years old

- Which is your guess?

Gastroscopy: Duodenal ulcer > 50% of the circumference



Gastroscopy: Duodenal ulcer > 50% of the circumference



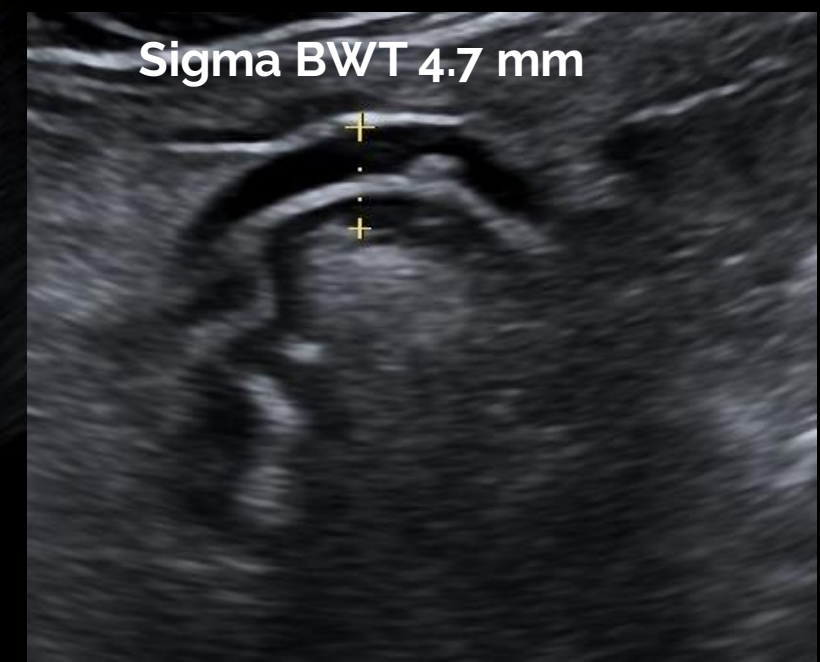
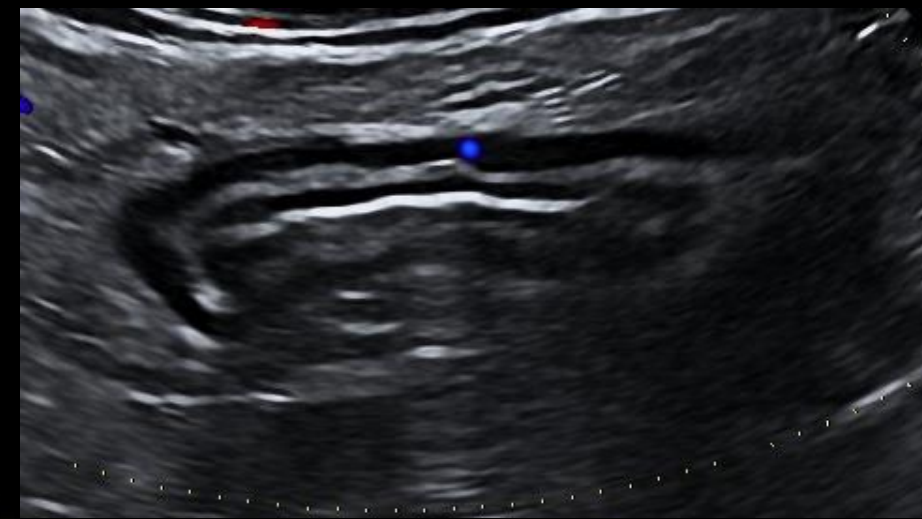
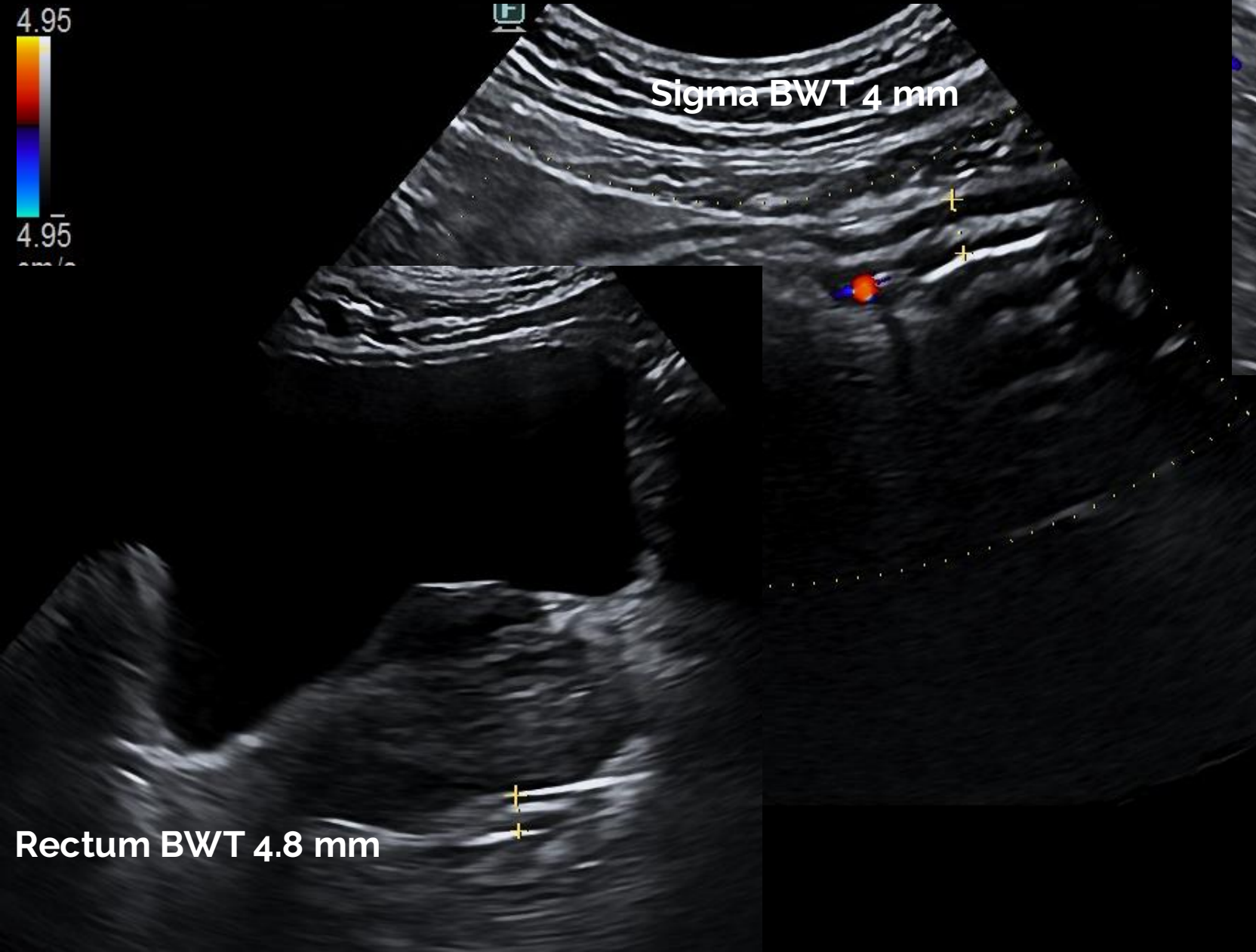
Giambattista, 54 years old

- First visit:
 - Ulcerative colitis since 2006, treated with mesalamine
 - Flare for 1 month with 13-14 stools daily, with blood and mucus. Abdominal pain, urgency, weight loss of 2 kg
 - CRP 23.2 mg/L, fecal calprotectin 1175
 - He is taking oral mesalazine 4 g/day and 2 g mesalazine enemas

Point-of-care intestinal ultrasound



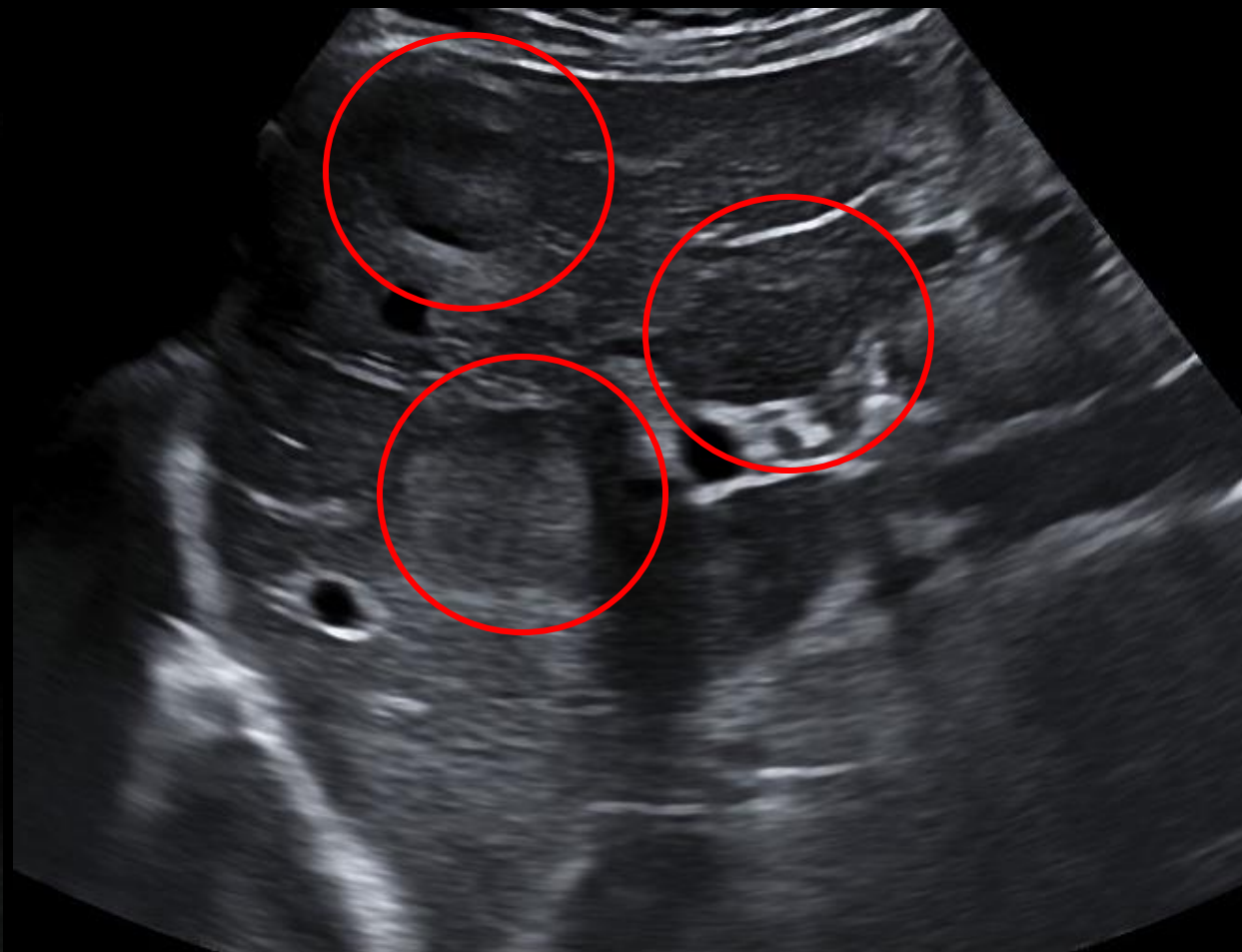
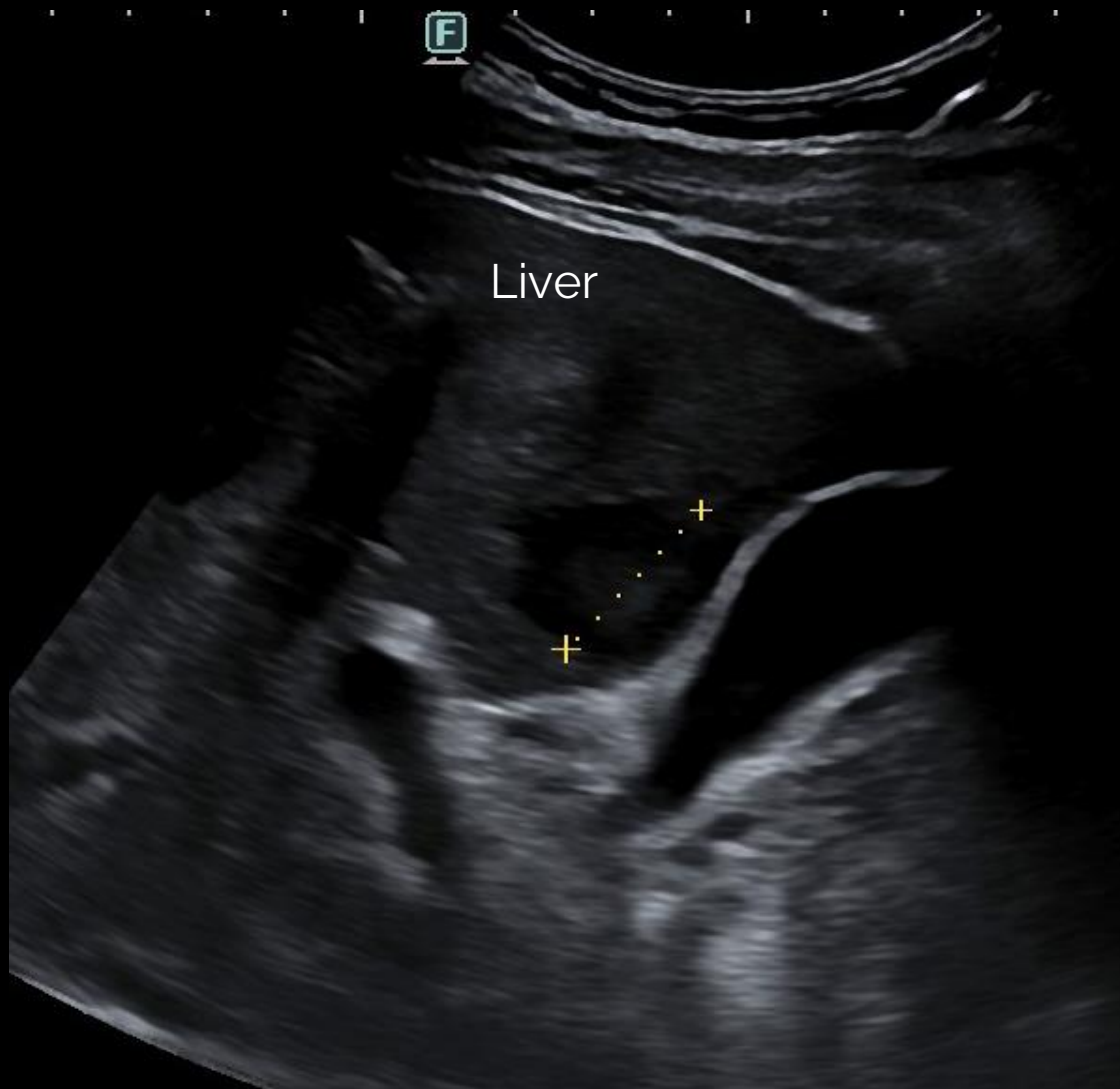international bowel
ULTRASOUND GROUP



Point-of-care intestinal ultrasound

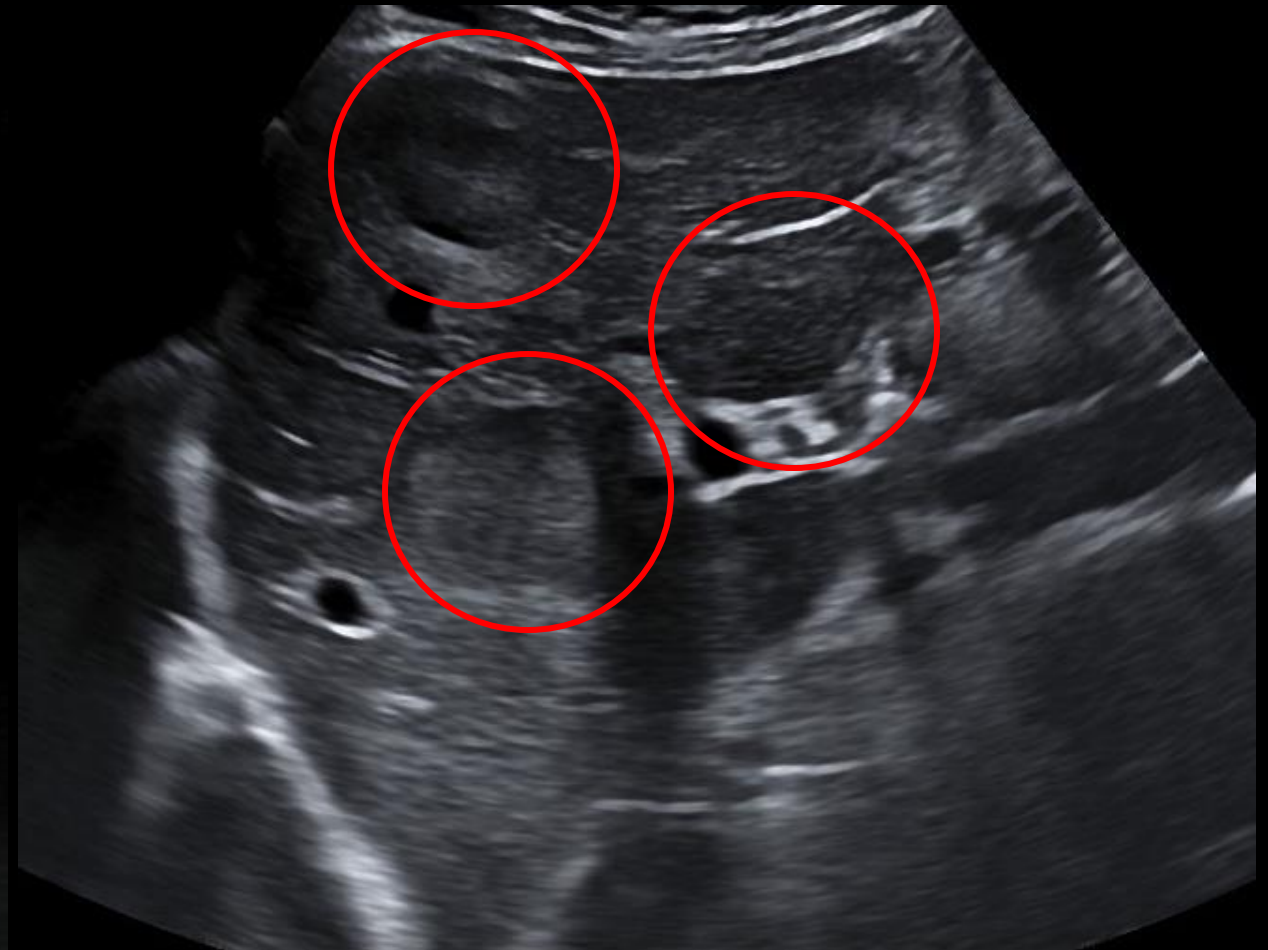
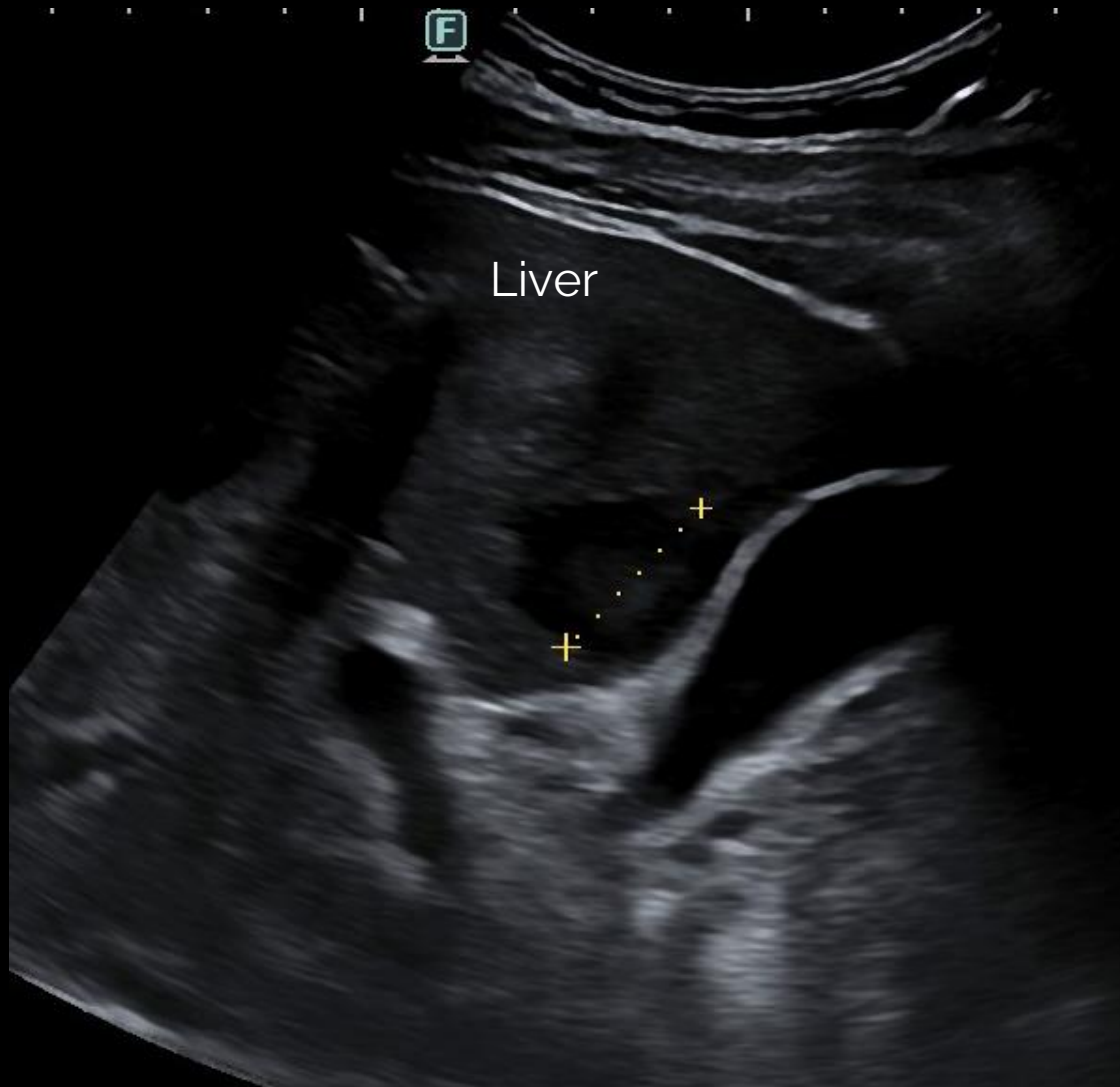

international bowel
ULTRASOUND GROUP



Dist: 25.1mm


Point-of-care intestinal ultrasound



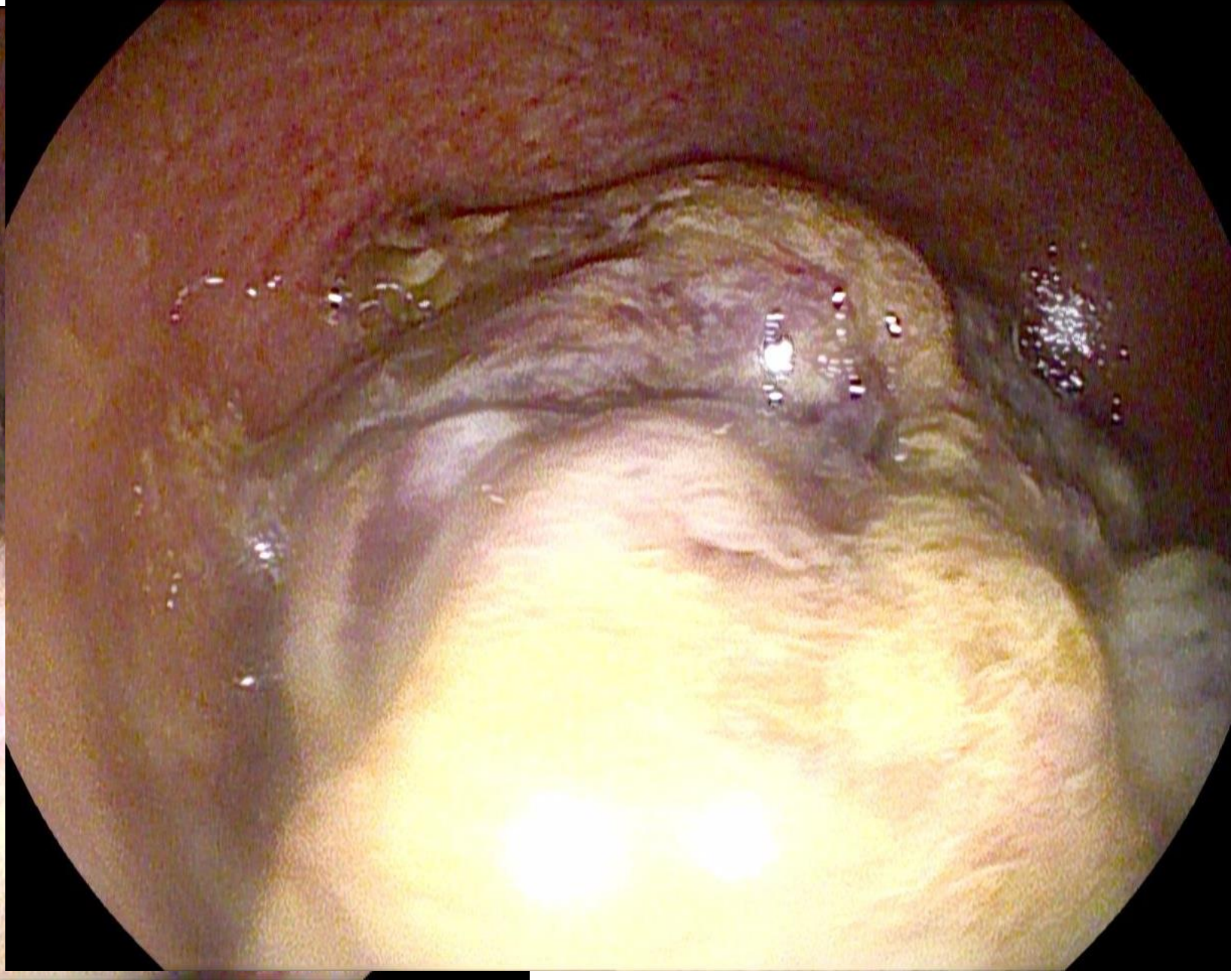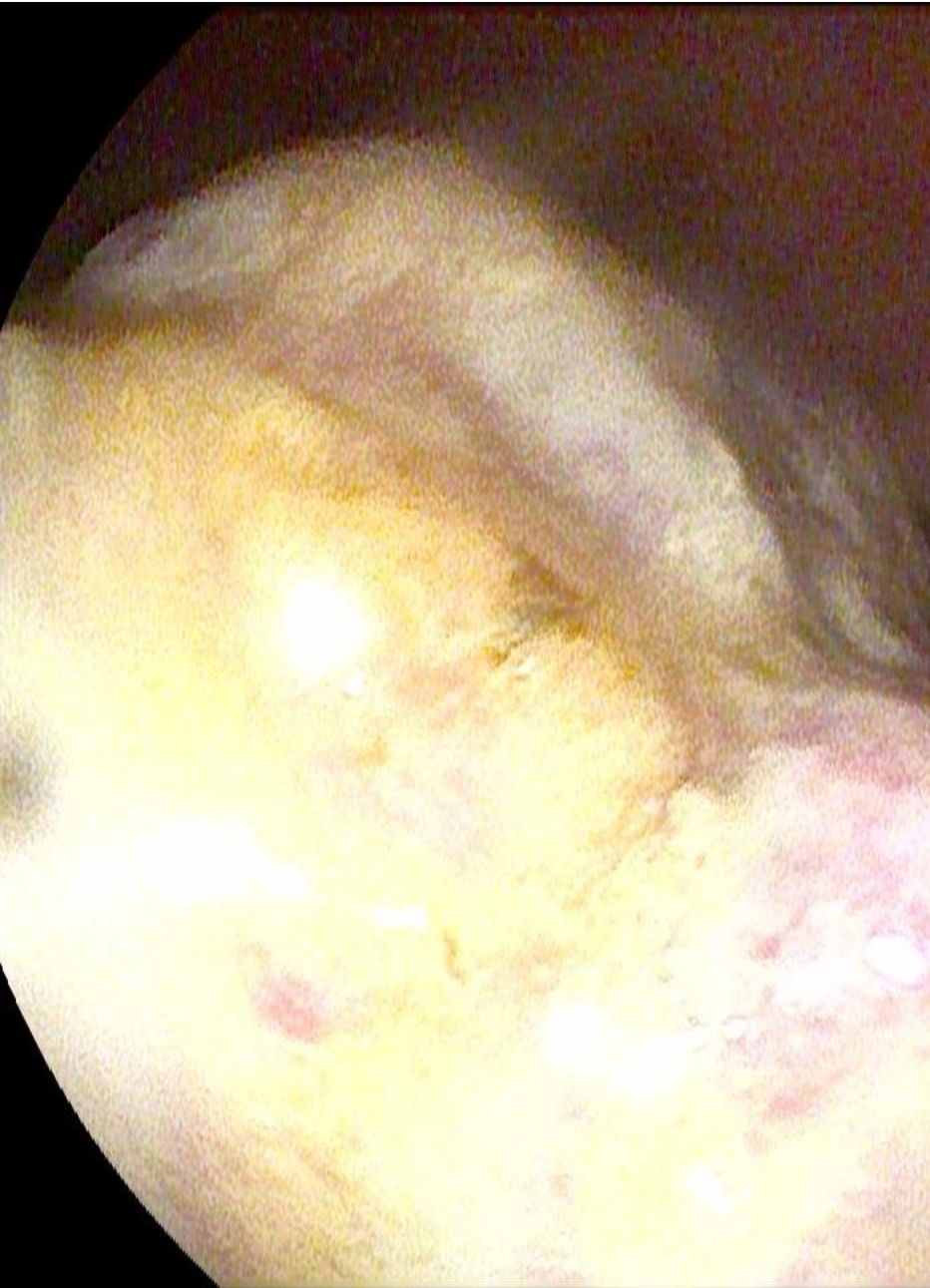
Dist: 25.1mm

CT scan confirmed liver metastasis

Colonoscopy: cancer of the rectum



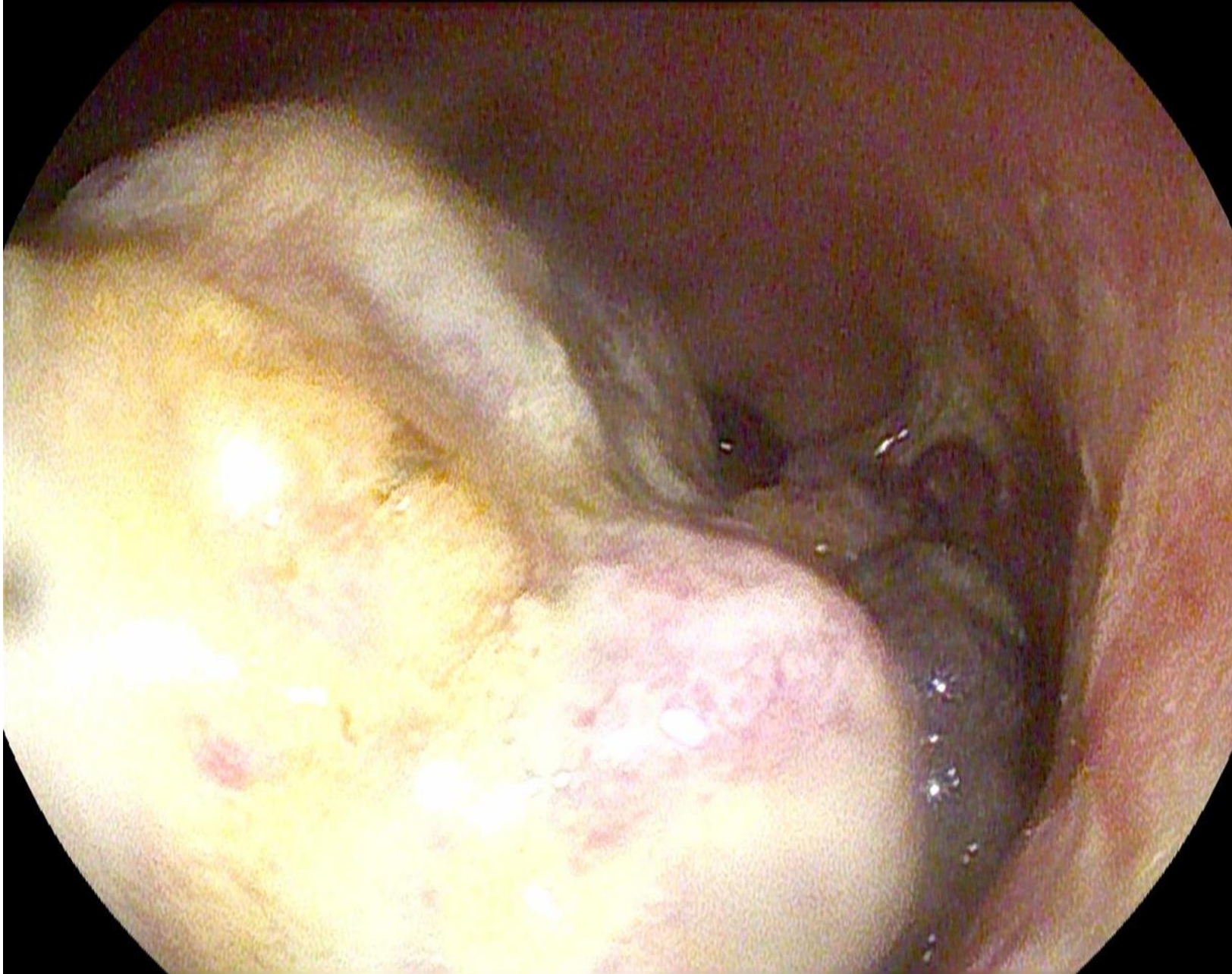
international bowel
ULTRASOUND GROUP



Colonoscopy: cancer of the rectum




international bowel
ULTRASOUND GROUP



Enrico, 56 years old

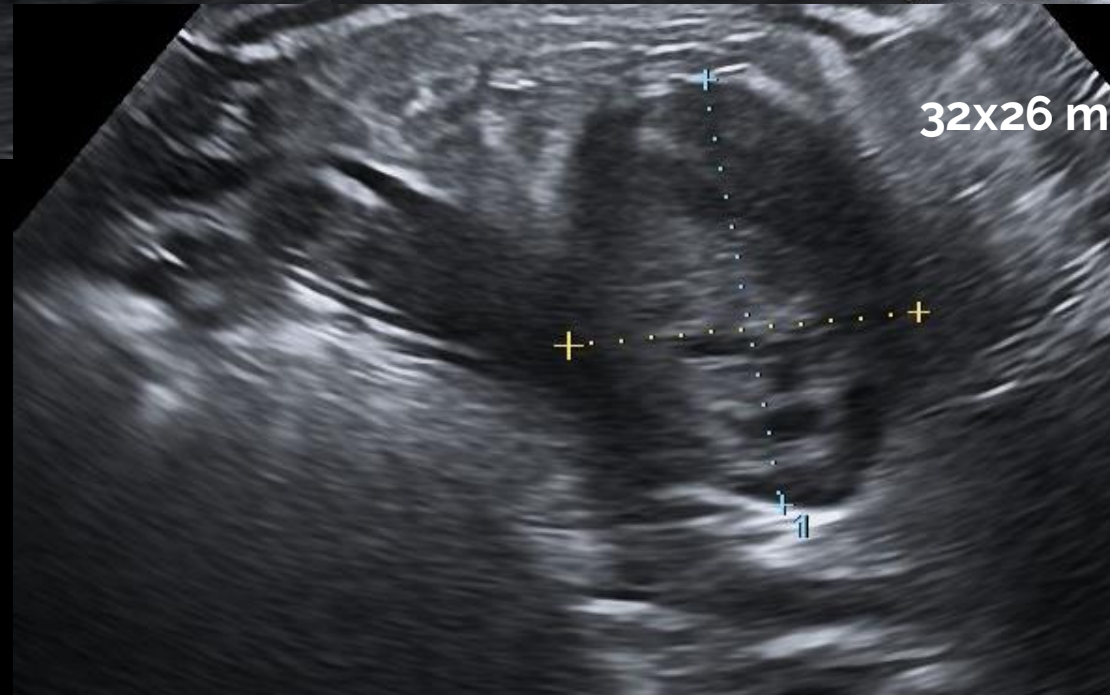
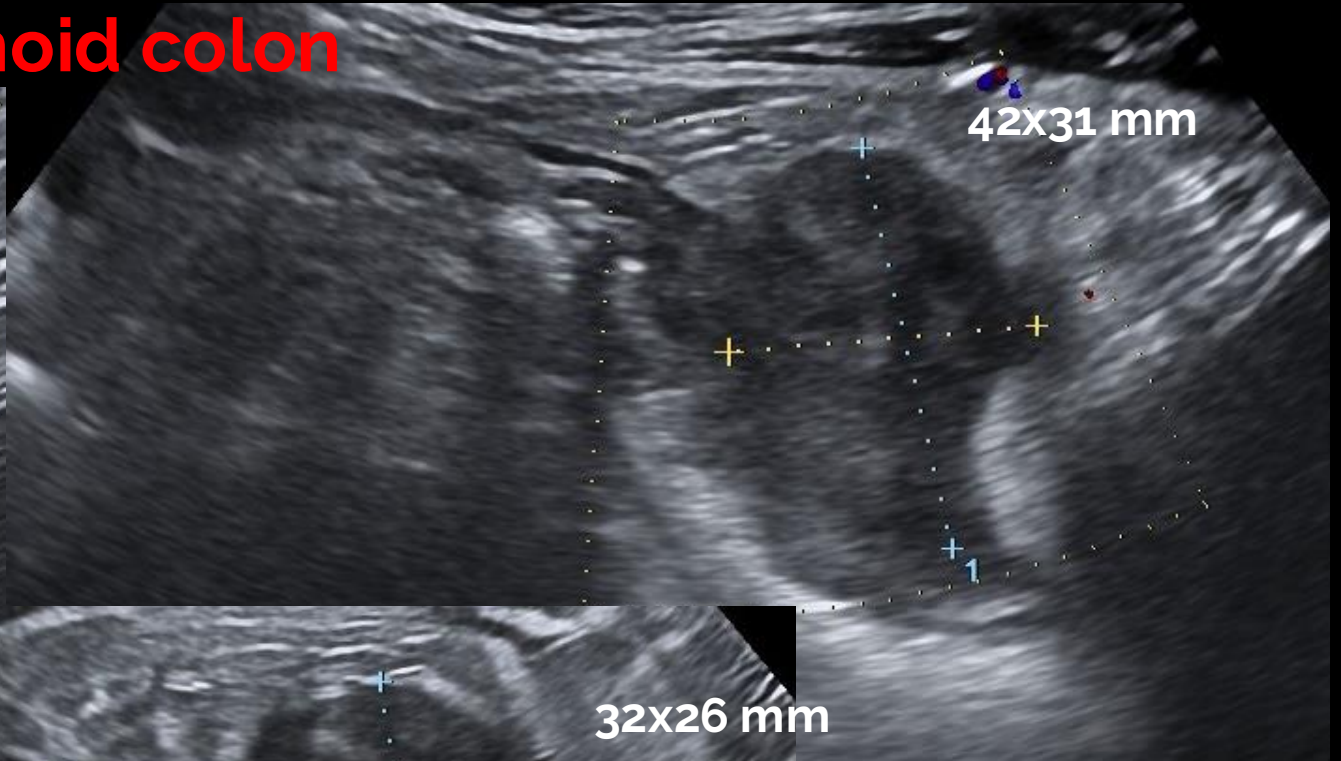
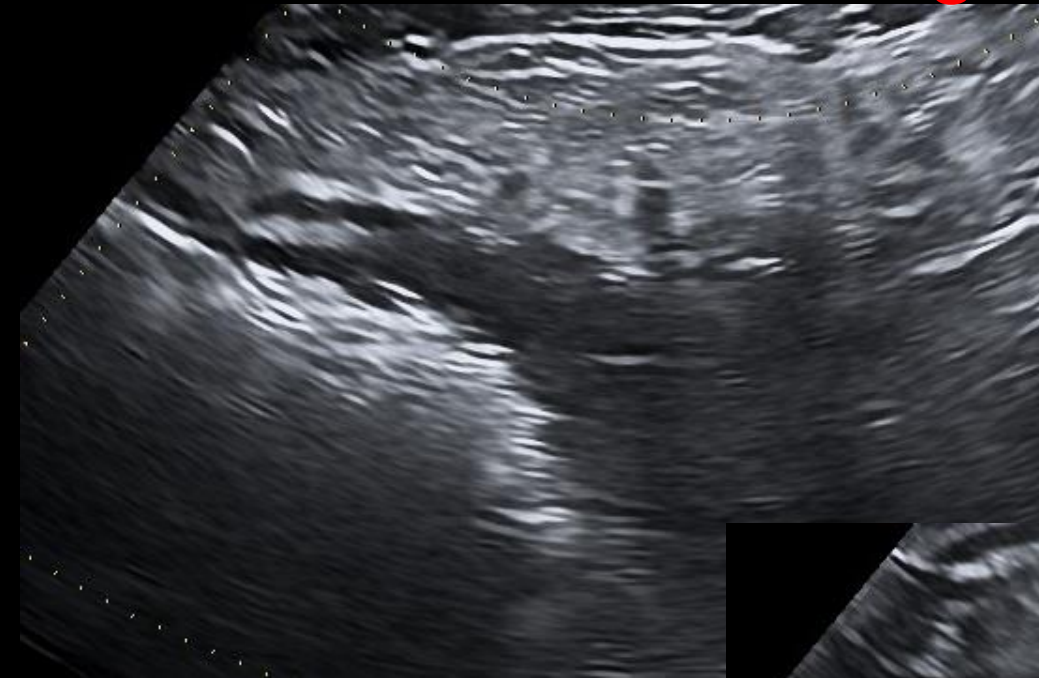- First visit:
 - Long-standing ulcerative colitis, since age 18
 - Mesalazine for five years after diagnosis, then stop
 - Last colonoscopy 30 years ago
 - Abdominal pain in left flank for a week

Point-of-care intestinal ultrasound



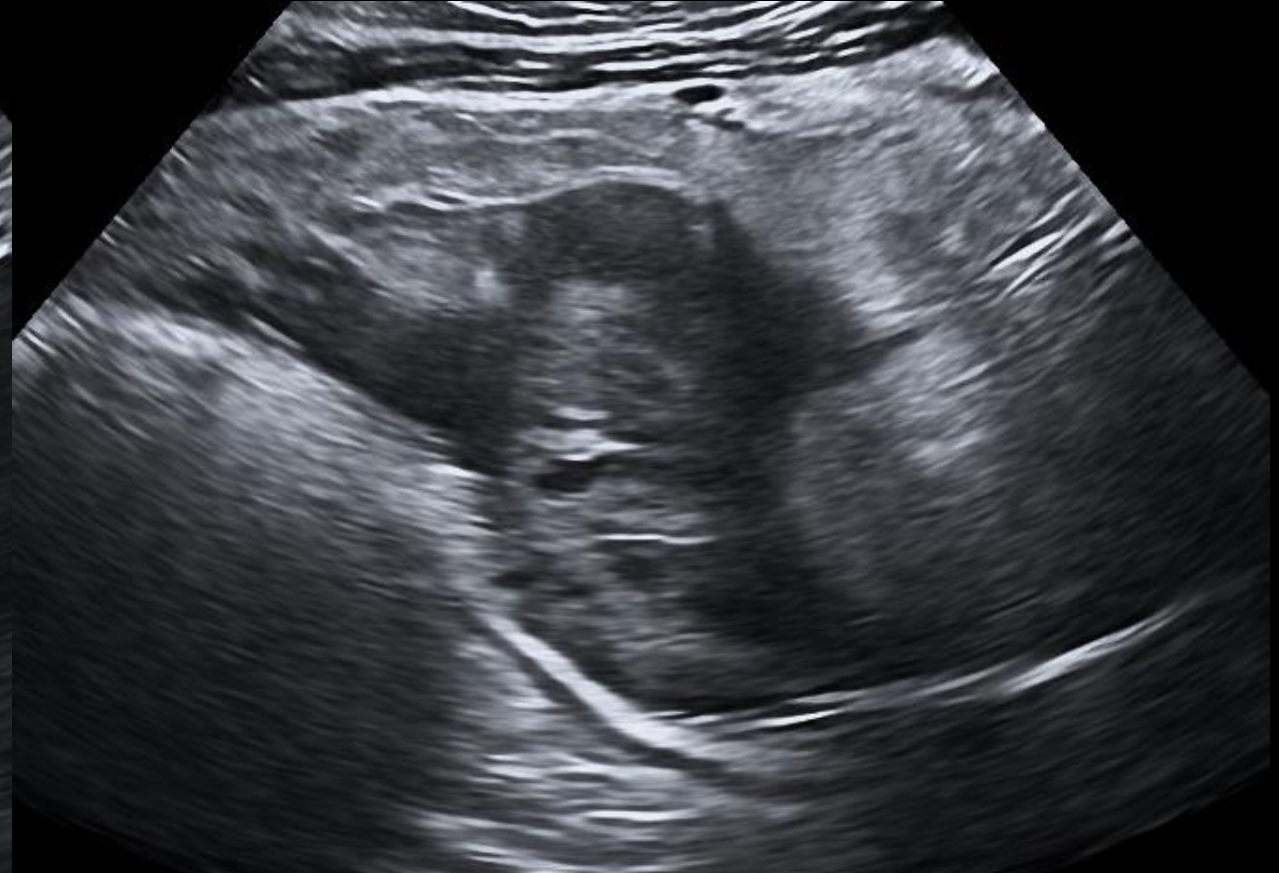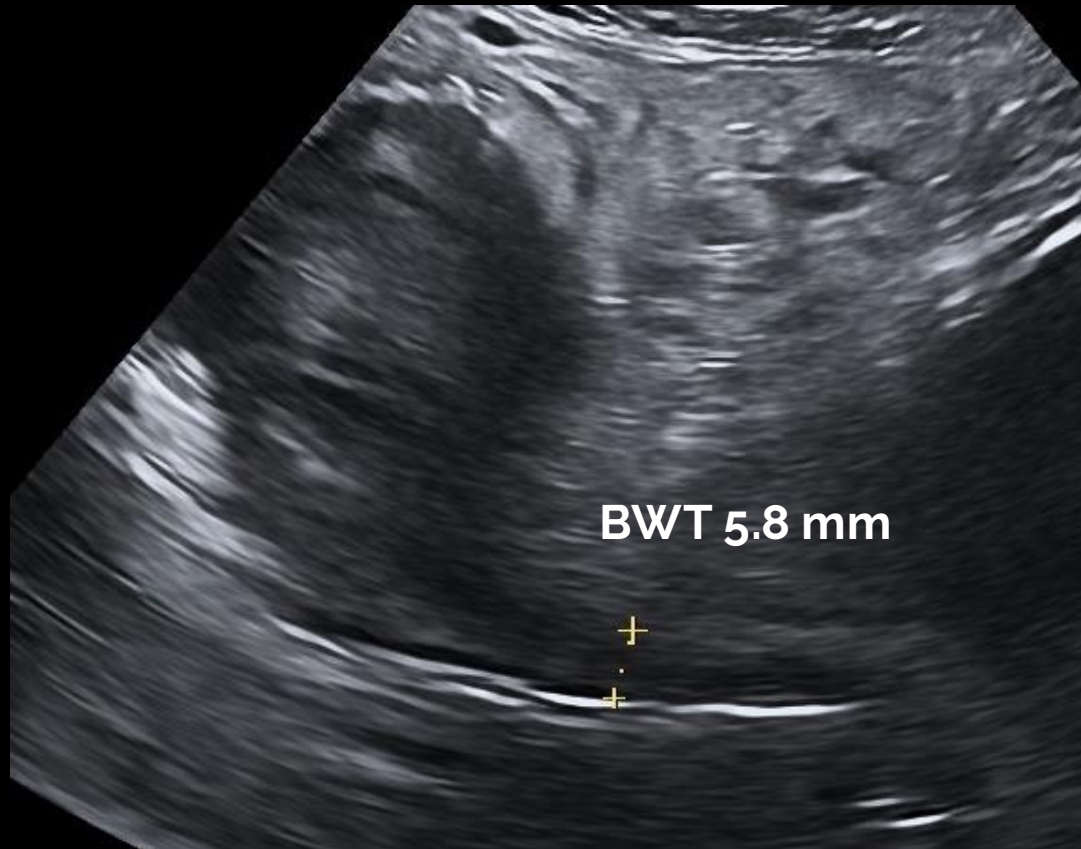
international bowel
ULTRASOUND GROUP

Sigmoid colon

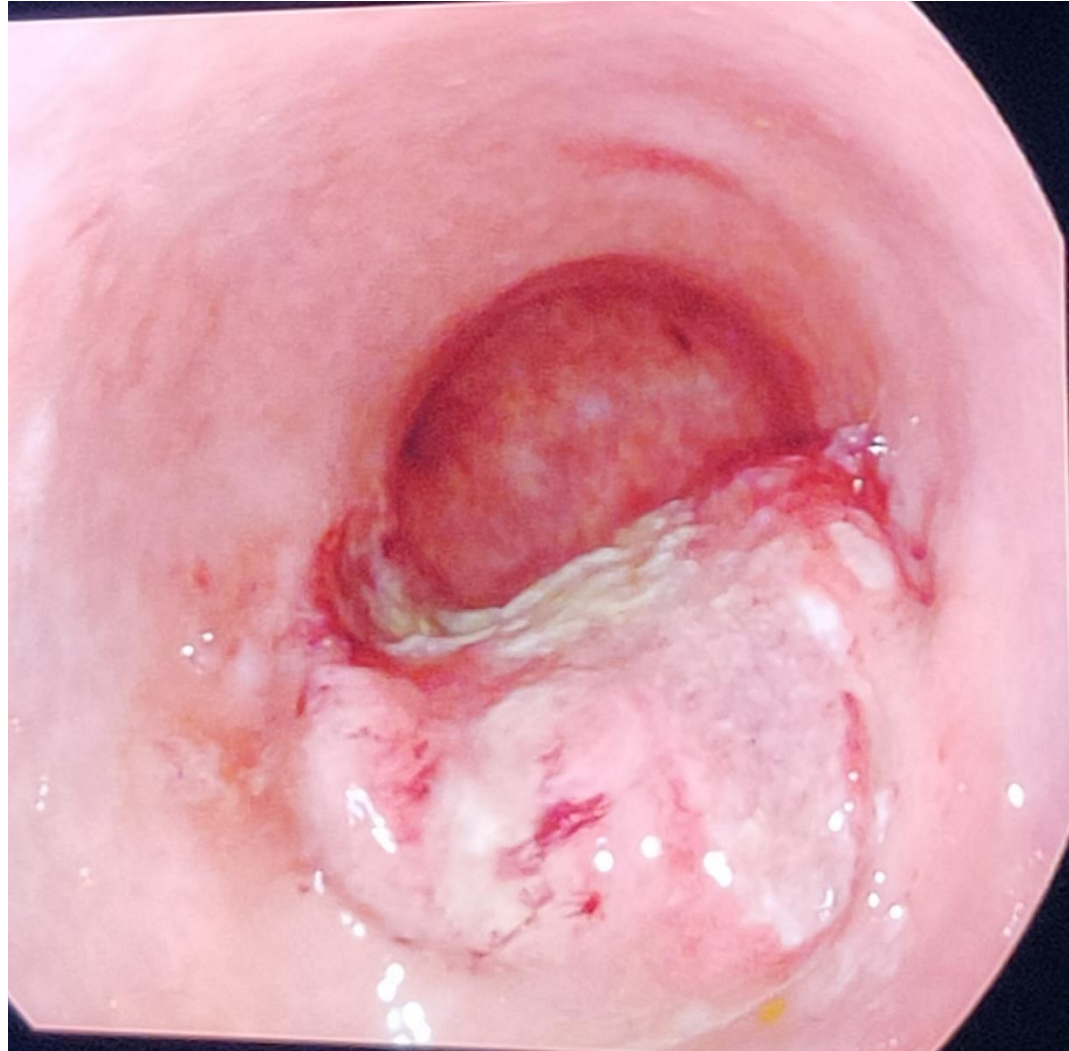




Sigmoid colon



Colonoscopy: cancer of sigmoid colon



Salem, 42 years old

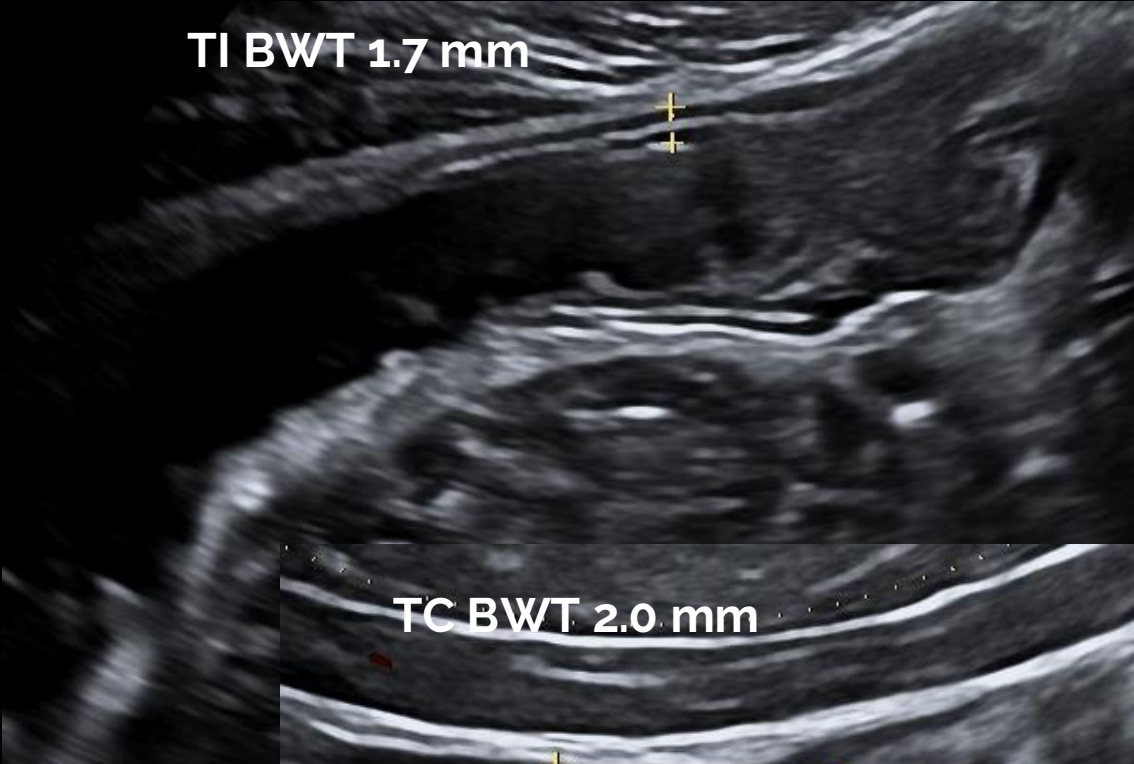
- First visit:
 - Watery diarrhea for three months, 20 stools per day, no blood
 - Stool cultures and Clostridium difficile toxin negative
 - Colonoscopy with diagnosis of microscopic lymphocytic colitis. No response to budesonide
 - Blood investigations: Hb 10.3 g/dL, MCV 87, WBC 4000, PLT 101000, K 3.05 mmol/L, CRP N, serology for celiac disease negative, thyroid function in normal range

Point-of-care intestinal ultrasound

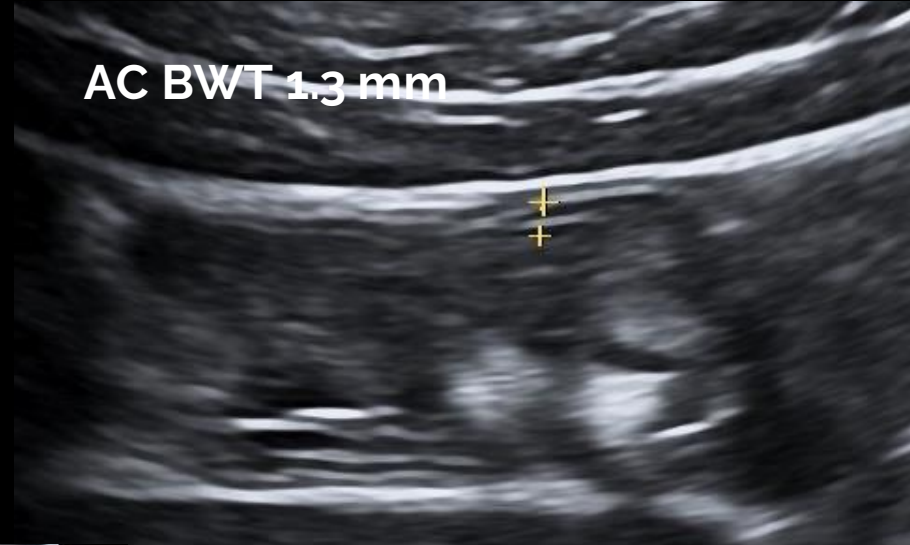


international bowel
ULTRASOUND GROUP

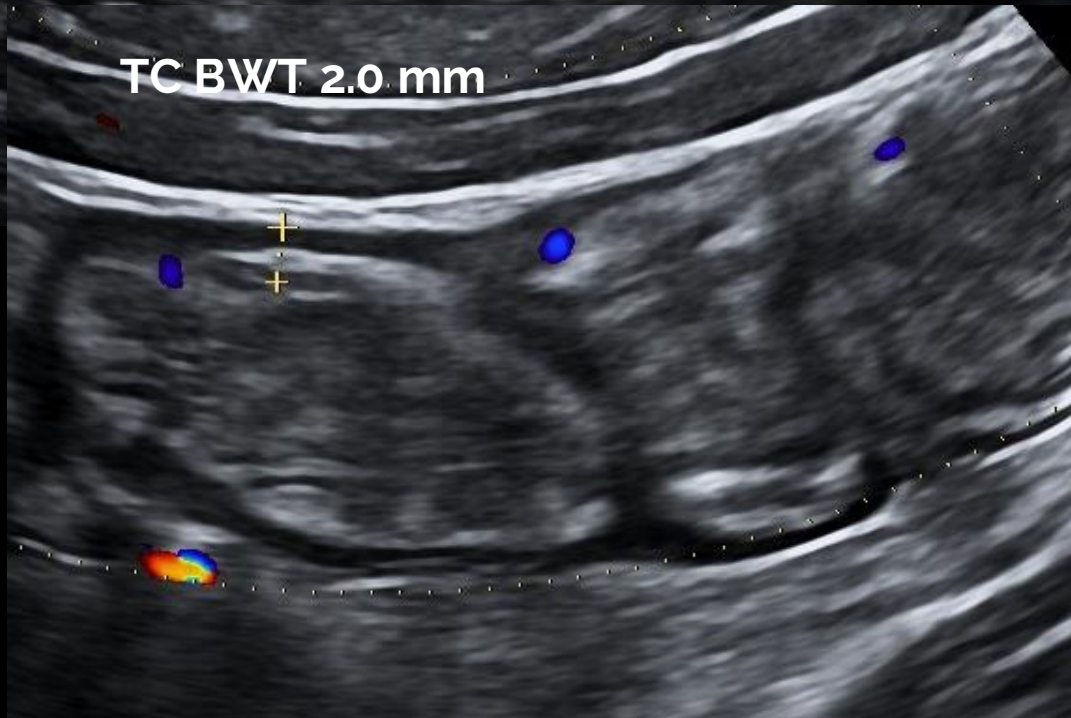
TI BWT 1.7 mm



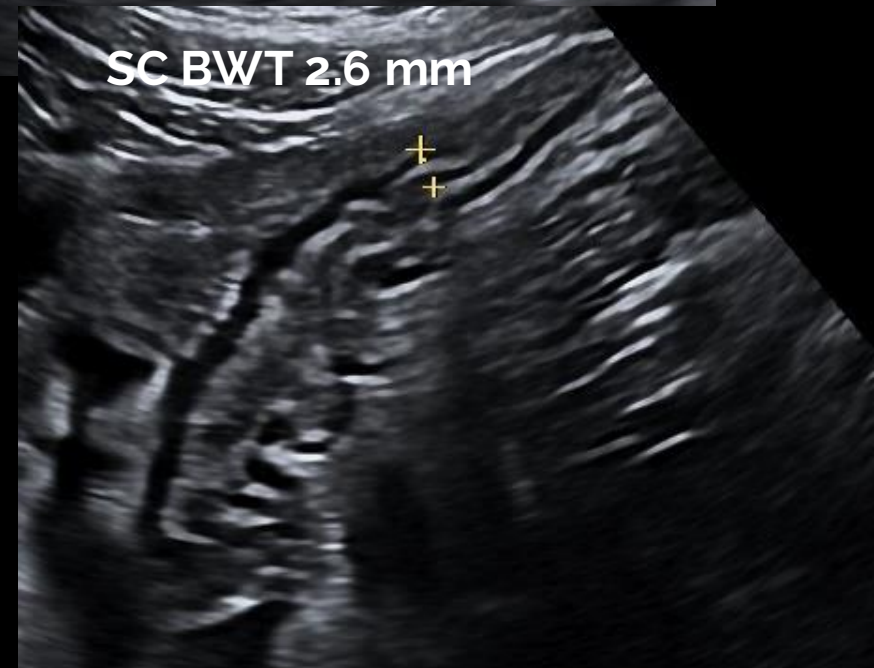
AC BWT 1.3 mm

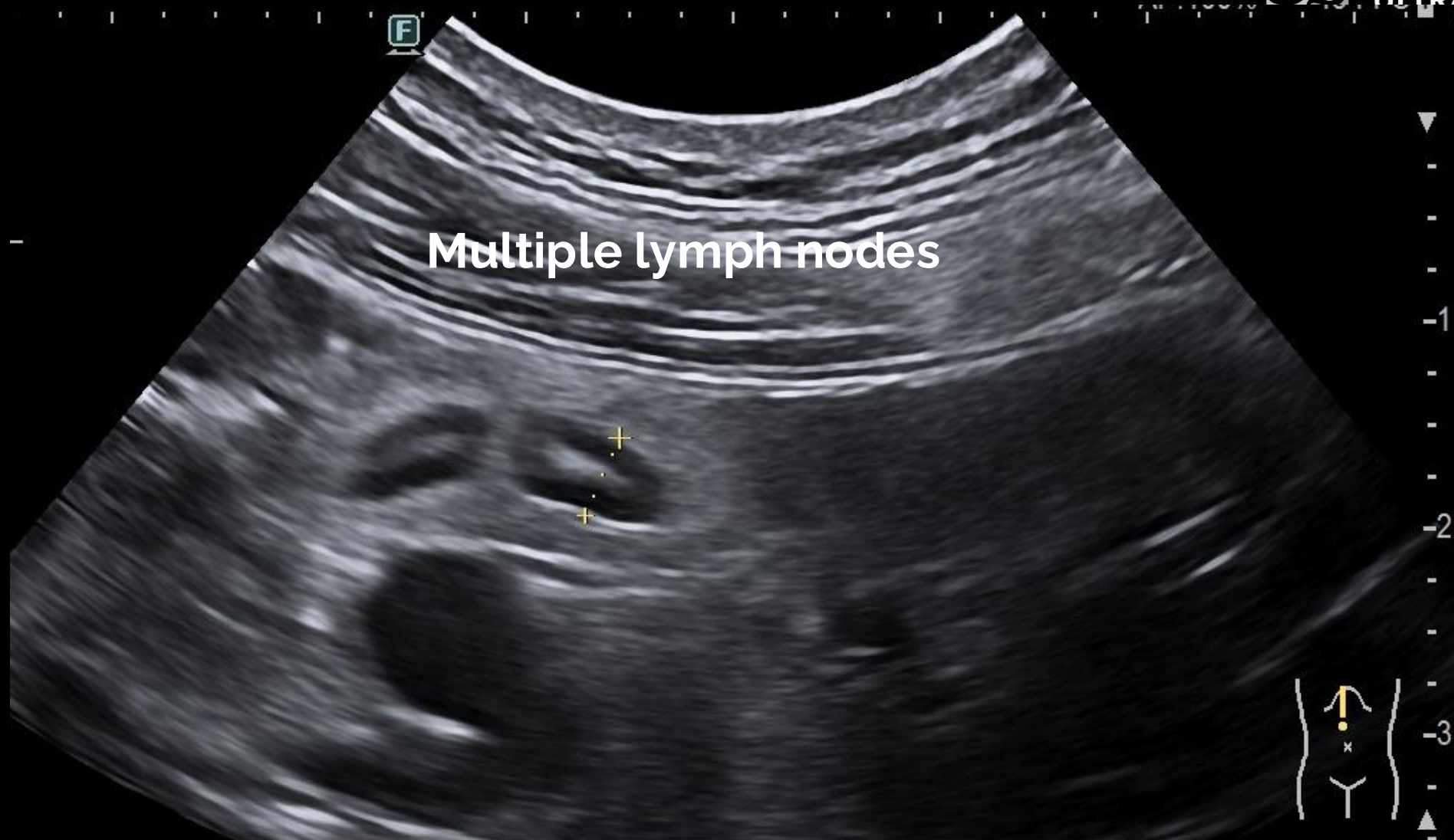


TC BWT 2.0 mm



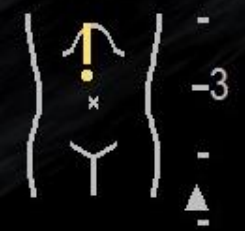SC BWT 2.6 mm



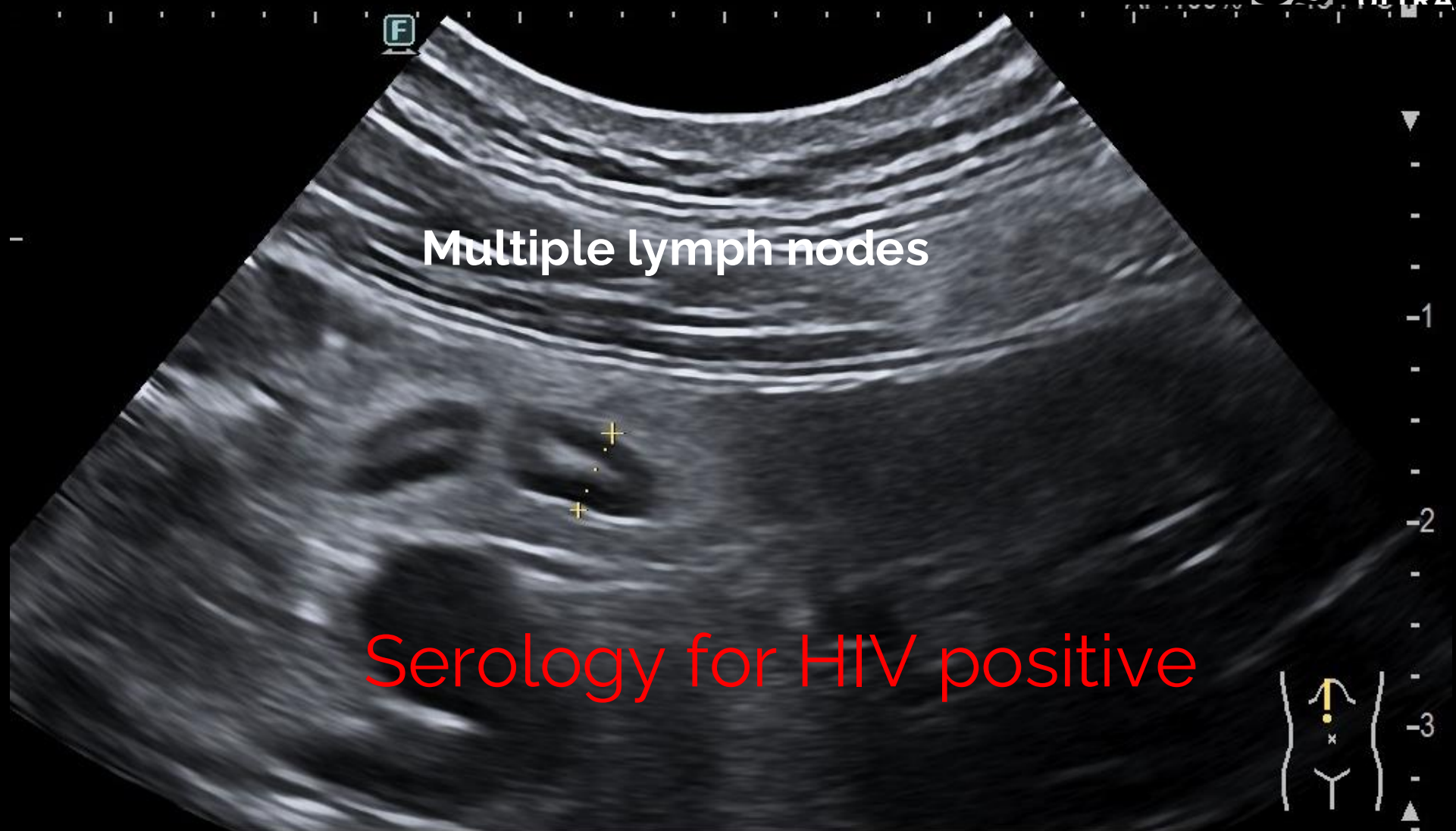

C42

Dist: 4.1mm



ANSE Micro.

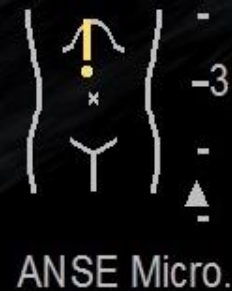

Multiple lymph nodes

Serology for HIV positive

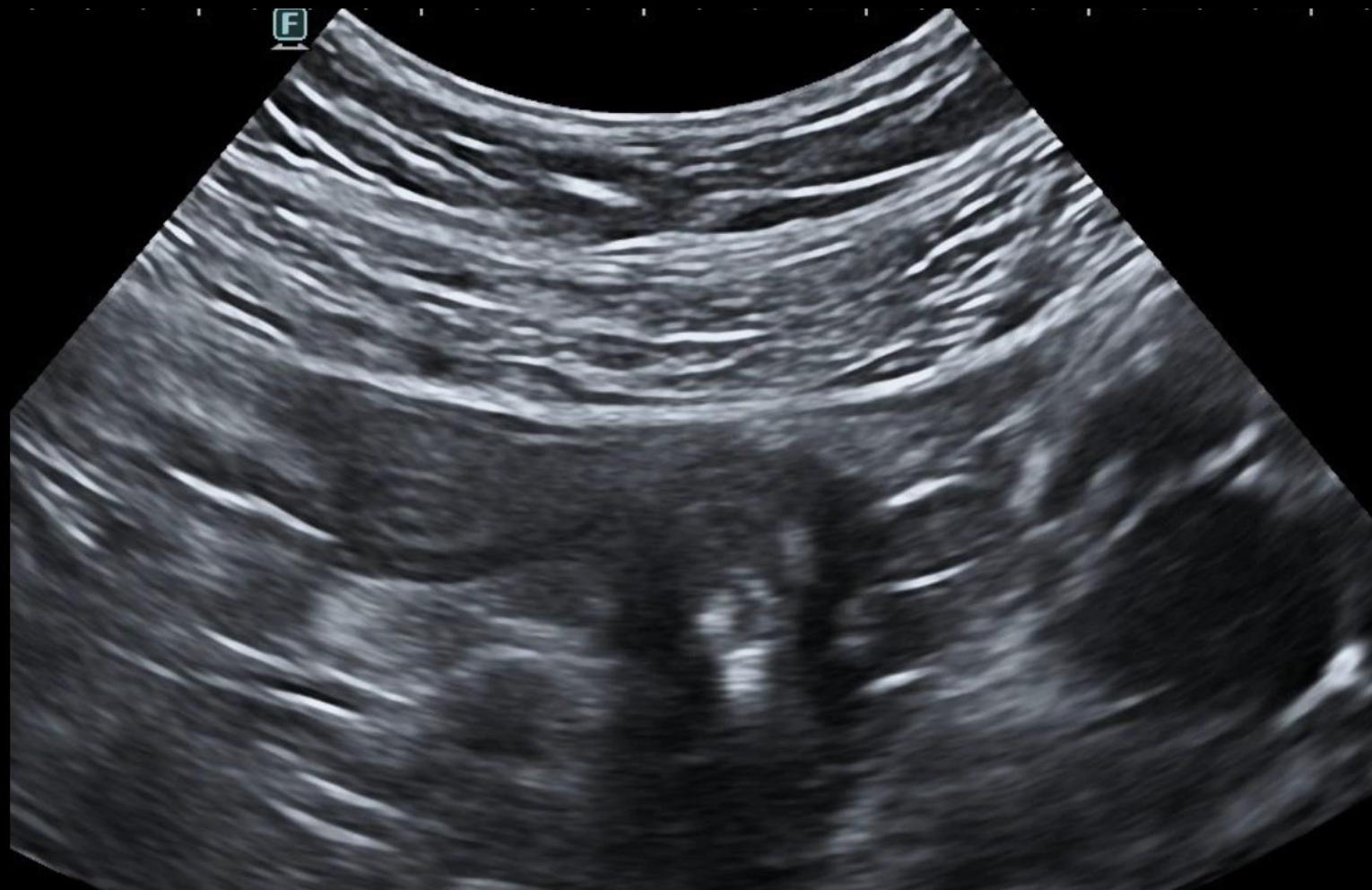C42

Dist: 4.1mm

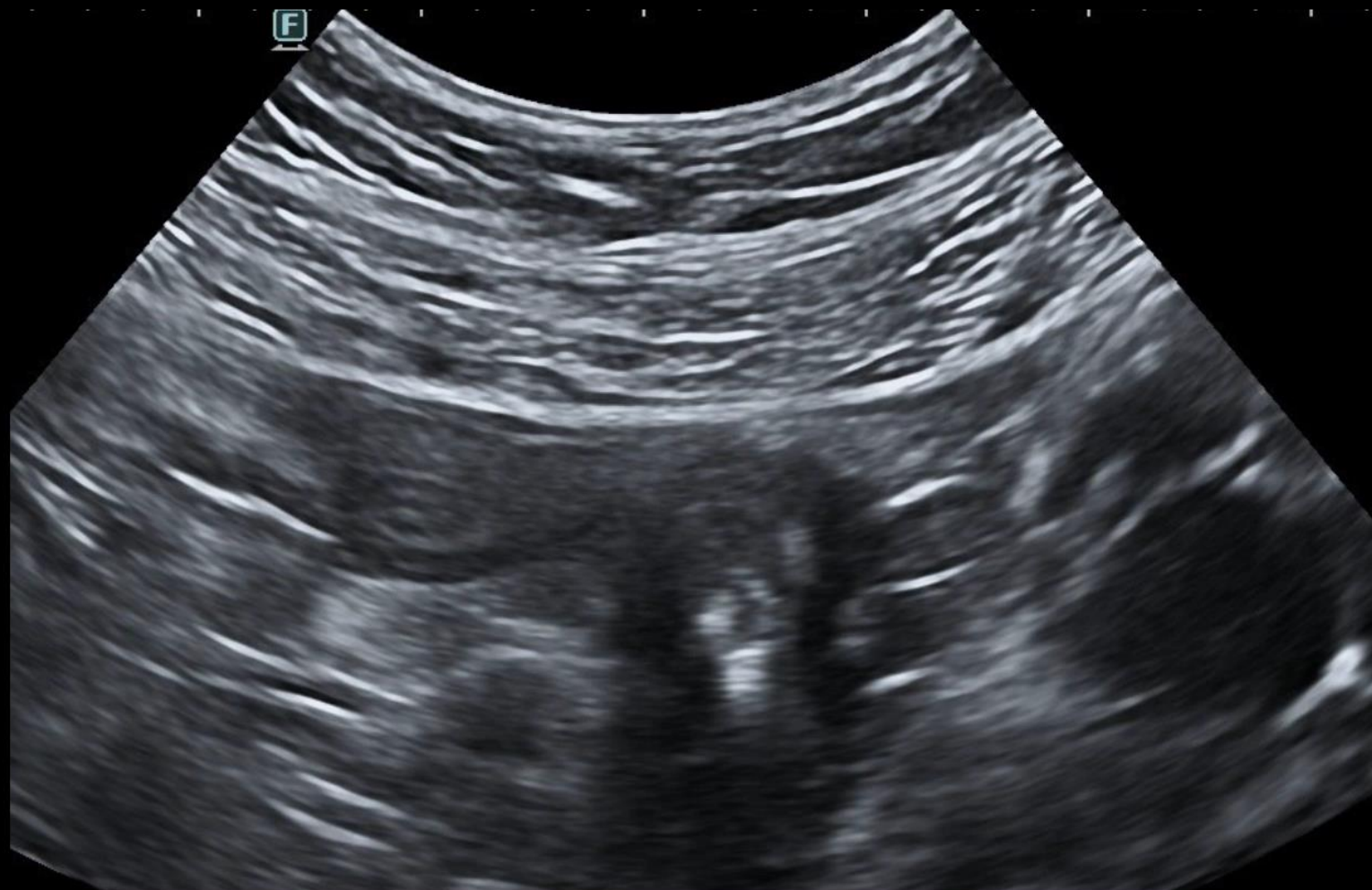

Last but not least

el
JP



Last but not least: Diverticulosis



Thank you